

**Case Report**

# Actinomycosis of the Gallbladder: A Case Report

Chih-Yuan Cheng<sup>1</sup>, Hung-Kan Tseng<sup>2</sup>, Shing-Jhong Long<sup>3</sup>,  
Shih-Sung Chuang<sup>4</sup>, Shien-Tung Pan<sup>5\*</sup>

<sup>1</sup>Department of Surgery, <sup>2</sup> Section of gastroenterology, department of Internal Medicine,  
<sup>3</sup>Department of Radiology, <sup>5</sup>Department of Pathology, Miaoli General Hospital, Miaoli City,  
Taiwan 36054

<sup>4</sup>Department of Pathology, Chi-Mei Medical Center, Tainan, Taipei Medical University,  
Taipei, and National Taiwan University, Taipei, Taiwan

## Abstract

**Introduction:** Actinomycosis of the gallbladder is extremely rare and may mimic a malignancy leading to delayed diagnosis and/or inappropriate treatment.

**Presentation of case:** Here we report the case of an 82-year-old man who presented with right upper abdominal discomfort for one month. Radiographically, an ill-defined mass was found in the gallbladder fossa that invaded the adjacent abdominal wall and liver bed. In addition, a stone was found in the gallbladder lumen. The imaging features suggested a gallbladder carcinoma. An initial CT-guided needle biopsy showed an inflammatory process. The subsequent open cholecystectomy revealed a contracted, thick-walled gallbladder surrounded by a soft tissue mass near the fundus. Histologically, the gallbladder revealed acute and chronic cholecystitis and microabscesses containing sulfur granules in the soft tissue mass, which showed Gram-positive filamentous bacilli. Under the diagnosis of gallbladder actinomycosis, the patient received post-operative antibiotics for 7 weeks and was well 5 months after diagnosis.

**Conclusion:** Our case demonstrated that a gallbladder actinomycosis should be considered in the differential diagnosis in patients with cholelithiasis and cholecystitis presenting an invasive mass in the gallbladder fossa.

**Keywords:** Actinomycosis; Gallbladder carcinoma; Taiwan

**Peer Reviewer:** Sanath Kumar, MD, Department of Radiation Oncology, Henry Ford Health System, United States

**Academic Editor:** Xiaoning Peng, MD, PhD, Hunan Normal University School of Medicine, China

**Received:** January 19, 2014; **Accepted:** March 1st, 2014; **Published:** March 18, 2014

**Competing Interests:** The authors have declared that no competing interests exist.

**Copyright:** 2014 Pan ST *et al.* This is an open-access article distributed under the terms of the Creative Commons Attribution License, which permits unrestricted use, distribution, and reproduction in any medium, provided the original author and source are credited.

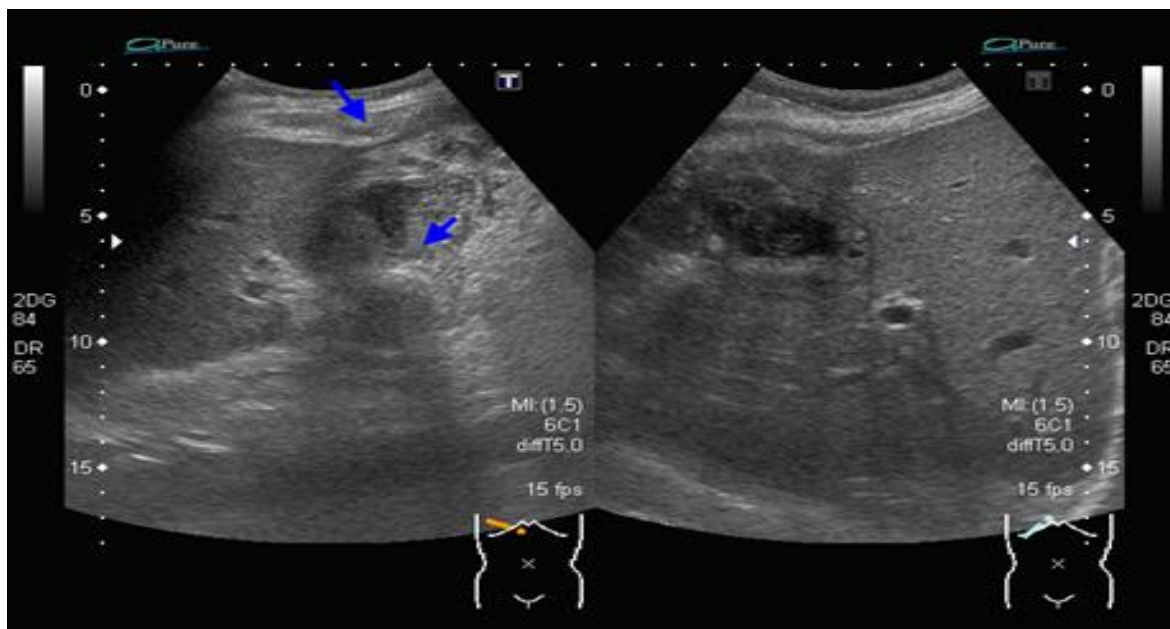
\***Correspondence to:** Shien-Tung Pan. Clinical Department of Pathology Miaoli General Hospital 747 Weigung Road Miaoli City, Taiwan, 36054 Email: [stpan.path@msa.hinet.net](mailto:stpan.path@msa.hinet.net)

## Introduction

Actinomycosis is a subacute or chronic suppurative disease caused by the opportunistic infection of Actinomycetes, a commensal gram-positive anaerobic filamentous bacterium normally inhabiting in the oropharynx, gastrointestinal tract, and female genital tract. The disease occurs when normal mucosal barrier is breached due to infection, trauma or surgery. It usually spreads continuously ignoring tissue planes with invasion of the surrounding structure and is characterized by abscess formation with granulation tissue and fibrosis that eventually leads to the formation of draining sinuses. The clinical manifestations are extremely variable but generally consist of inflammation with draining abscesses, fistula or mass lesion. *Actinomyces israelii* is the most common isolated species. Other species including *A. gerencseriae*, *A. naeslundii*, *A. viscosus*, *A. odontolyticus*, and *A. meyer* may rarely produce disease [1-3]

Clinically actinomycosis is classified according

to the anatomical site of infection. Cervicofacial actinomycosis is the most common type, comprising 50% of all reported cases, and is usually closely related to oral surgery or poor dental hygiene [1-2]. Both thoracic and abdominopelvic lesions account for one fifth of the cases. Abdominal actinomycosis occurs in patients with predisposing factors such as acute appendicitis, particularly with perforation, gastrointestinal perforation, previous surgery, neoplasia, and foreign bodies in the gastrointestinal tract or genitourinary tract [1-2]. Women with long term use of intrauterine devices are predisposed to pelvic actinomycosis [2, 4]. Actinomycosis of the gallbladder is extremely rare, with less than 50 cases described in English literatures [5-6], and has never been reported in Taiwan yet. Clinical diagnosis of actinomycosis of gallbladder is challenging because the lesion may mimic a malignancy. Here we report a patient with actinomycosis of gallbladder mimicking carcinoma, who was successfully treated with open cholecystectomy followed by antibiotics treatment.



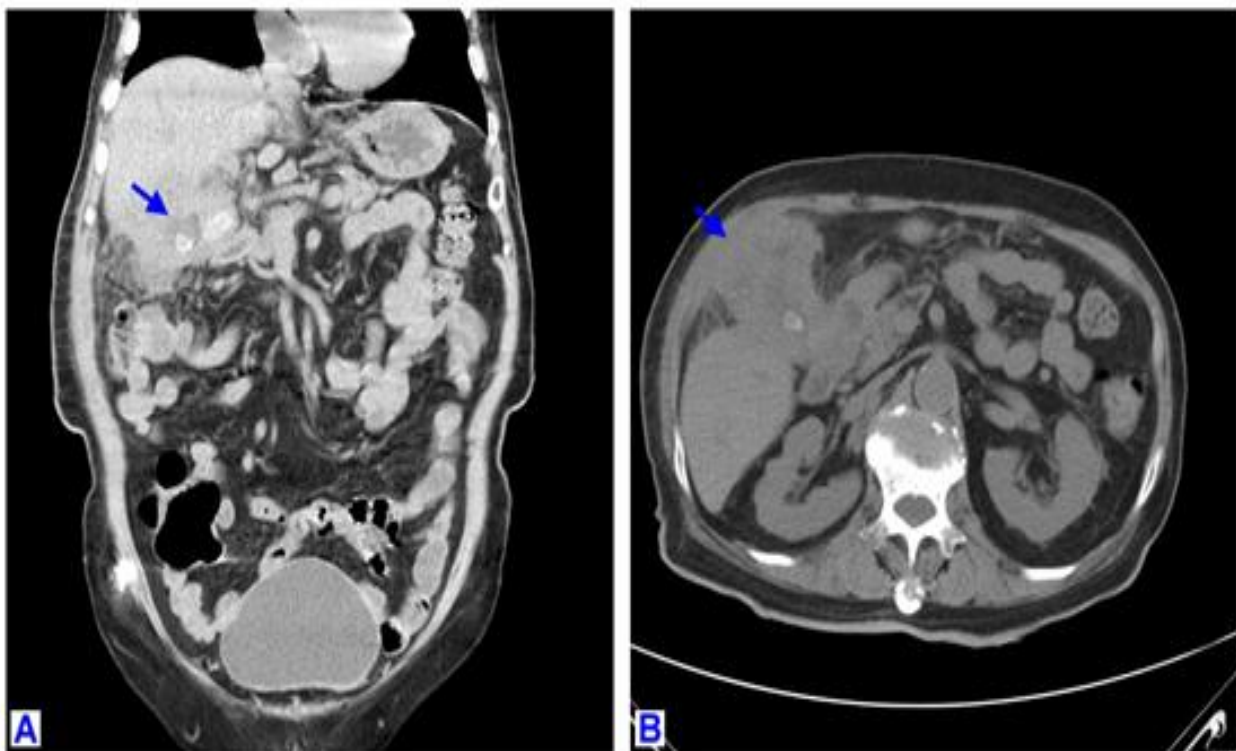
**Figure 1** Ultrasonography of the abdomen showed irregular thickening of gallbladder wall with invasion to liver bed and abdominal wall (arrow, upper), and an echogenic shadowing in the gallbladder lumen (arrow, lower). The imaging suggested a gallbladder carcinoma.

## Case report

An 82-year-old man presented with poor appetite and generalized weakness for one month. His past history included hypertension and diabetes mellitus (DM) under regular medical control. He lost more than 10 Kg weight in one year. On physical examination, local tenderness at the right upper abdominal quadrant was found. Laboratory data showed mild anemia, elevated white cell count

(10,830/uL), increased serum levels of CRP (16.12 mg/dL), alkaline phosphatase (574 IU/L), and r-GT (107 U/L). Serum CA-125 was elevated (61.3 U/ml).

Ultrasonography (US) and computerized tomography (CT) scans showed an ill-defined mass in the gallbladder fossa, 8.6 x 4.5 cm in size, associated with a calcified gallstone in the lumen (Fig. 1 & 2, respectively).



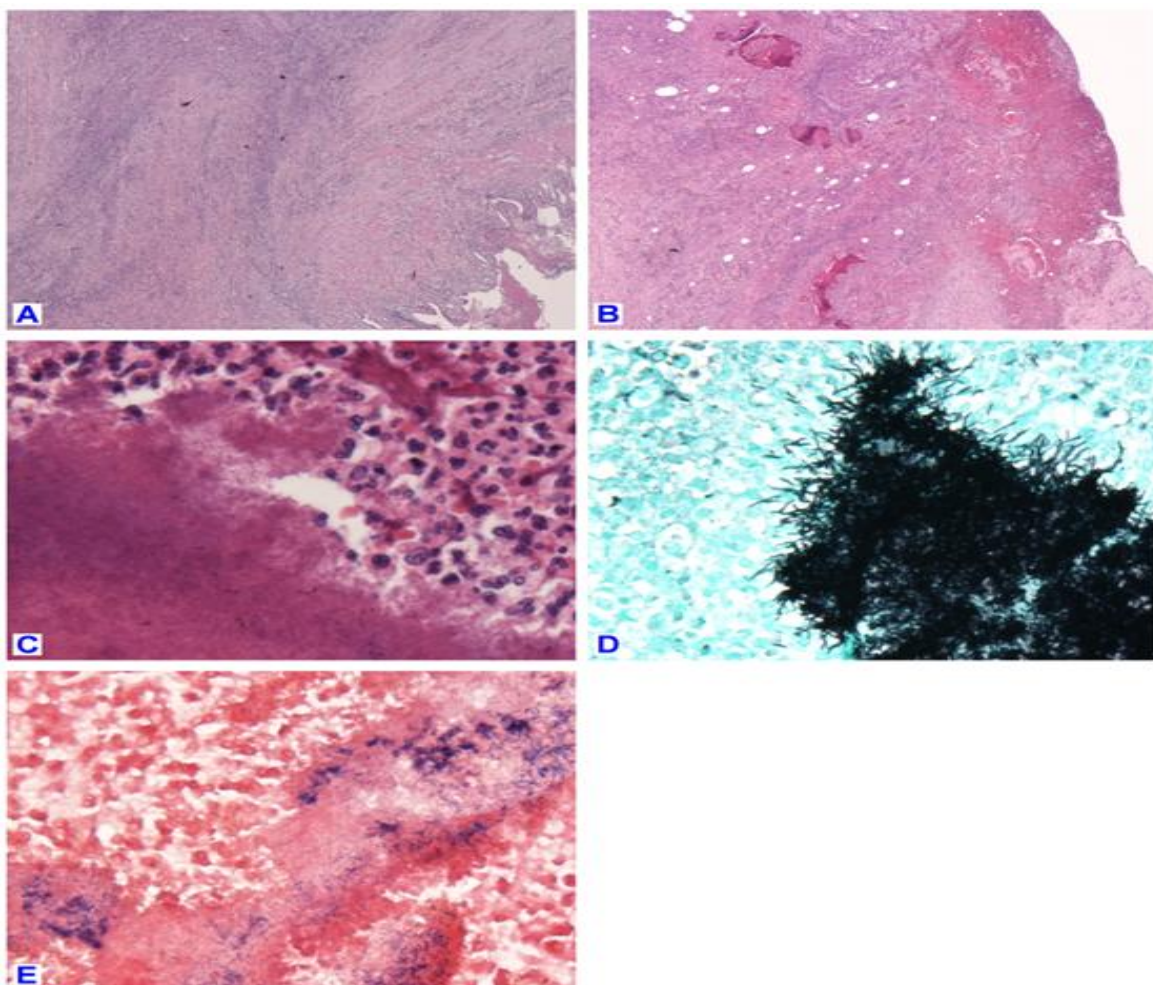
**Figure 2A & 2B:** Sagittal (2A) and transverse view (2B) on CT of whole abdomen without contrast enhancement showed one soft tissue mass with ill-defined border over gallbladder fossa, a calcified gallstone (2A, arrow), and with invasion to right abdominal wall and liver (2B, arrow). The picture was highly suspicious for gallbladder carcinoma.

The imaging findings suggested a gallbladder carcinoma with invasion to the right abdominal wall and liver bed. CT-guided core biopsy of the soft mass revealed fibrous tissue with chronic active inflammation suggesting abscess formation. Subsequent open cholecystectomy showed a contracted gallbladder with thickened wall adhering to the surrounding tissue and focal

hemorrhagic necrosis near the fundus. A soft mass existed between the gallbladder and the peritoneum that was overlaid by the greater omentum. The lesion adhered to but not invaded the duodenal wall. Grossly, the mass contained an abscess cavity containing pus, which showed *Escherichia coli* (*E. coli*) by culture. In addition, a gallbladder stone was present in the gallbladder lumen.

Histologically, the gallbladder showed acute and chronic cholecystitis with thickened wall heavily infiltrated by foamy histiocytes and lymphocytes (Fig. 3A). The surrounding soft tissue showed hemorrhage and necrosis. Focally, multiple discrete abscesses containing “sulfur granule” was discernible in the inflamed wall (Fig. 3B). In routine hematoxylin and eosin (H&E) stain, the sulfur granules revealed acellular eosinophilic materials with peripheral radiation. Periodic

Acid-Schiff (PAS) and Grocott Hexamine-Silver (GMS) stain demonstrated tangled filamentous microorganisms of Gram-positive bacteria in these granules (Fig. 3C-E). Acid-fast stain was negative. The morphological findings were pathognomonic for actinomycosis. The patient received post-operative treatment with intravenous ampicillin plus sulbactam in the initial 3 weeks, followed by one month of oral amoxicillin. He was well 5 months after the diagnosis.



**Figure 3A:** The gallbladder wall showed chronic cholecystitis with thickening and prominent infiltration of inflammatory cells (haematoxylin and eosin stained; original magnification, x 20).

**Figure 3B:** Hemorrhagic necrotic tissue showed several abscesses containing amorphous eosinophilic “sulfur granule” (haematoxylin and eosin stain; original magnification, x 20).

**Figure 3C:** The sulfur granules surrounded by prominent neutrophils showed peripheral radiation and contained bacterial colonies (haematoxylin and eosin stain; original magnification, x 600).

**Figure 3D:** Tangled filamentous bacilli were demonstrated in the sulfur granule with Grocott Hexamine-Silver (GMS) stain (GMS stain; original magnification, x 600).

**Figure 3E:** Gram stain showed gram-positive bacteria in the sulfur granule (Gram stain; original magnification, x 600).

## Discussion

Abdominopelvic actinomycosis is one of the most frequent mimickers of carcinoma. Actinomycosis of the gallbladder is extremely rare, with less than 50 cases reported in the English literature [5-6]. The disease tends to mimic gallbladder cancer both clinically and radiographically, and is, therefore, difficult to diagnose pre-operatively; almost all patients with the disease were recognized after histological examination. Clinically, gallbladder actinomycosis presents with subacute or chronic cholecystitis, usually with distention or thickening of gallbladder wall. Perforation or abscess formation may cause adhesion with the adjacent structures, forming a mass lesion mimicking a carcinoma [3]. Lee et al. reviewed 14 patients with actinomycosis of gastrointestinal tract and proposed that the most common CT features for diagnosing abdominopelvic actinomycosis were thickened bowel wall and regional pelvic or peritoneal mass with extensive infiltration [7]. In our patient, an abdominal CT scan revealed a mass lesion in the gallbladder fossa with invasion to the abdominal wall and liver bed, suggesting a carcinoma. The correct diagnosis was made only after histological examination. Similarly, in the study of Kuo et al., eight in ten cases of abdominopelvic actinomycosis underwent radical surgery because the disease mimicked malignancy [4].

Histological diagnosis of actinomycosis is based on the demonstration of "sulfur granules" associated with purulent inflammation. However, sulfur granules can occasionally be present in other bacterial infections such as *Nocardia brasiliensis*, *Streptomyces madurae*, and *Staphylococcus aureus* [1]. In addition, sulfur granules are detected in only 50% of patients with actinomycosis [4]. In spite of this, sulfur granules with microorganism of tangled gram-positive filamentous bacteria are pathognomonic for diagnosing actinomycosis [1]. Actinomyces are slow-growing micro-organisms that need to be cultured on selective agar medium

at 37°C anaerobically for up to three weeks. Without clinical suspicion and appropriate culturing condition, isolation of actinomyces is likely to be missed out.

Elevated tumor markers such as CA-125 and/or CA-199 in the serum had been reported in patient with actinomycosis [8]. In our case, serum CA-125 not AFP, CEA or CA-199 was elevated. CA-125 is a member of glycoproteins and is used as a biomarker for screening and monitoring patients with ovarian cancers. However, serum CA-125 can also be elevated in various non-neoplastic conditions, such as TB peritonitis or non-specific inflammatory processes in the peritoneum, pleura, and pericardium [9]. Therefore, patients with abdominopelvic actinomycosis and elevated CA-125 may highly suggest a malignancy, particularly when associated with invasive features in the imaging studies.

The route of infection in gallbladder actinomycosis is not clear. Since most species of Actinomyces are not able to grow in bile acid, a retrograde infection from duodenum through bile duct is one of the possible routes [3, 10]. Hematogenous spread can be another course of infection although there was no infection source outside the gallbladder fossa in our patient [2].

Actinomycosis usually occurred in immunocompetent persons but a high proportion of patients of gallbladder actinomycosis were associated with gallbladder stone or other underlying diseases [6]. Mir et al. reviewed 14 patients with gallbladder actinomycosis and two patients with bile duct actinomycosis. They found that 10 had stones in the gallbladder or bile duct, two had DM; and eight were associated with other diseases including liver tumor, liver abscess, gallbladder carcinoma, amyloidosis, myocardial infarction, rheumatoid arthritis, glomerulonephritis, and heart failure. Only 7 patients were free of any underline diseases [6]. The high proportion of patients having coexistent gallbladder stone or other diseases may indicate the possible role of cholelithiasis as a predisposing factor in gallbladder actinomycosis .

Antimicrobial therapy is recommended for initial treatment in most cases of actinomycosis, while surgery can be used as an adjunctive therapy in selective cases. Penicillin G is the drug of choice for all clinical forms [1]. However, in the study of Kuo et al., surgical intervention alone can cure patients with abdominopelvic actinomycosis by complete removal of infectious foci without the need for long-term antibiotic treatment [4]. Synergistic microbes are usually identified in actinomycosis, most commonly anaerobic gram-negative bacilli. They act as copathogens that enhance the low invasiveness of actinomyces to establish an infection by inhibiting host defense. In our case, *E. coli* was isolated in the pus drained from the abscesses. In a review of actinomycosis, Smego & Foglia recommended that there was no need to direct antimicrobial therapy against the synergistic copathogens as treatment regimens against actinomyces were usually also effective for the co-pathogens [2].

## Conclusion

Actinomycosis of gallbladder is extremely rare and can be challenging in clinical diagnosis. Similar to the lesions located in the gastrointestinal tract, gallbladder actinomycosis tends to mimic a carcinoma. Diagnosis of this disease in most patients is delayed until histological examination. Our case demonstrated that a gallbladder actinomycosis should be considered in the differential diagnosis in patients with cholelithiasis and cholecystitis presenting an invasive mass in the gallbladder fossa.

## References

1. MoniruddinABM, Begum H, Nahar K. Actinomycosis: an update. *Medicine Today*. 2010, 22:43-47
2. Smego RA, Foglia G Actinomycosis. *Clin Infect Dis*. 1998, 26:1255-1263
3. Lee YH, Kim SH, Cho MY, Rhoe BS, Kim MS. Actinomycosis of the gallbladder mimicking carcinoma: a case report with US and CT findings. *Korean J Radiol*. 2007, 8: 169-172
4. Kuo YH, Hsieh PS, Changchien CR, Chen JS, Tang RP, Wang JY, Chiang JM, Yeh CY, Tsai WS, Hung HY. Abdominopelvic actinomycosis-treatment outcomes at the Chang Gung Memorial Hospital during the past 16 years. *J Soc Colon Rectal Surgeon (Taiwan)*. 2009, 20:49-55
5. Al-Sindi K, El-Shenawi H, Al-Hilli F. Actinomycosis of the gallbladder. *Bahrain Med Bull*. 2006, 28:1-7
6. Mir Y, McLaughlin E, Campbell F, Azadeh B. Actinomycosis of the gallbladder: a case report. *Open Mycol J*. 2008, 2:105-107
7. Lee IJ, Ha HK, Park CM, Kim JK, Kim JH, Kim TK, Kim JC, Cho KS, Auh YH. Abdominopelvic actinomycosis involving the gastrointestinal tract: CT features. *Radiol*. 2001, 220:76-80
8. Fu PK, Tsai CA. Management of patients with huge pelvic actinomycosis complicated with hydronephrosis: a case report. *J Microbiol Immunol Infect*. 2010, 43:442-446
9. Bae SY, Lee JH, Park JY, Kim D, Min BH, Rhee PL, Kim JJ. Clinical significance of serum CA-125 in Korean females with ascites. *Yonsei Med J*. 2013, 54:1241-1247
10. Hefny AF, Torab FC, Joshi S, Sebastian M, Abu-Zidan FM. Actinomycosis of the gallbladder: case report and review of the literature. *Asian J Surg*. 2005, 28:230-232