

## Case Report

# Severe Intracranial Hypertension Associated with Tetracycline Use in Non-Small Cell Lung Cancer

Hao-Wen Sim<sup>1,2</sup>, FRACP; Dean Cugley<sup>1</sup>, MBBS; Neil Shuey<sup>3</sup>, FRACP; Graham Lakkis<sup>4</sup>, FACO; and Linda Mileschkin<sup>1</sup>, FRACP

<sup>1</sup> Division of Cancer Medicine, Peter MacCallum Cancer Centre, East Melbourne, Australia

<sup>2</sup> Department of Medical Oncology and Haematology, Princess Margaret Cancer Centre, Toronto, Canada

<sup>3</sup> Department of Neuro-Ophthalmology, Royal Victorian Eye and Ear Hospital, East Melbourne, Australia

<sup>4</sup> Department of Optometry and Vision Science, University of Melbourne, Parkville, Australia

### Abstract

**Introduction:** Erlotinib has become an established treatment for patients with non-small cell lung cancer harbouring an epidermal growth factor receptor (EGFR) mutation. Tetracycline antibiotics are commonly prescribed for erlotinib-induced acneiform rash. A rare but morbid complication of tetracycline use is intracranial hypertension, an association which has not been reported in the oncology literature.

**Presentation of Case:** We report a case of severe intracranial hypertension in a patient with non-small cell lung cancer. Risk factors were prolonged tetracycline use and leptomeningeal carcinomatosis. Initial investigations were unhelpful, necessitating a high index of suspicion.

**Conclusion:** Tetracycline antibiotics, which are commonly prescribed for erlotinib rash, are an important risk factor for intracranial hypertension. Our patient developed severe vision loss from papilloedema, despite normal neuroimaging and relatively low opening pressure on lumbar puncture. Continuous intracranial pressure monitoring can be a valuable investigation in such circumstances.

**Keywords:** intracranial hypertension; pseudotumour cerebri; tetracycline; minocycline; non-small cell lung cancer

**Academic Editor:** Xiaoning Peng, Hunan Normal University School of Medicine, China

**Received:** May 18, 2015; **Accepted:** July 8, 2015; **Published:** August 1, 2015

**Competing Interests:** The authors have declared that no competing interests exist.

**Consent:** The patient was deceased at the time of manuscript preparation. As per correspondence with the editorial board, the requirement for consent has been waived.

**Copyright:** 2015 Sim HW *et al.* This is an open-access article distributed under the terms of the Creative Commons Attribution License, which permits unrestricted use, distribution, and reproduction in any medium, provided the original author and source are credited.

**\*Correspondence to:** Hao-Wen Sim, Department of Medical Oncology and Haematology, Princess Margaret Cancer Centre, Toronto, Canada

**Email:** Hao-Wen.Sim@uhn.ca

## Introduction

The development of targeted therapies against oncogene-addicted molecular pathways have transformed oncology practice. Advanced non-small cell lung cancers with activating mutations in the epidermal growth factor receptor (EGFR) are now treated with EGFR inhibitors such as erlotinib [1, 2].

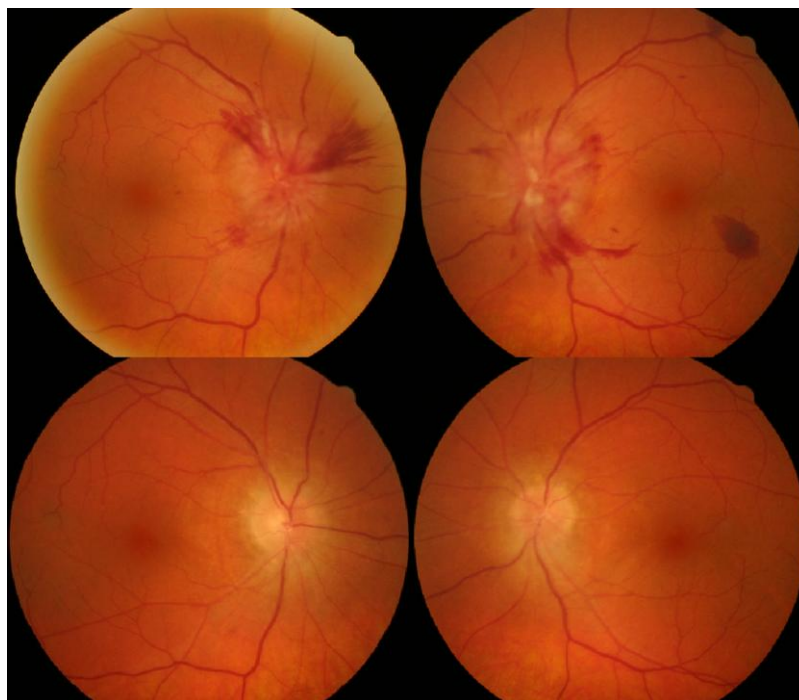
A frequent adverse effect of EGFR inhibitors is development of acneiform rash. Moderate to severe rash occurs in 8 to 12 percent of patients, and treatment guidelines recommend use of tetracycline antibiotics [3-5].

Intracranial hypertension is an uncommon but serious complication of tetracycline use. This association may not be well recognised by medical oncologists. A high index of clinical suspicion is required as the diagnostic workup can be imprecise and misleading.

## Case presentation

A 58-year-old Italian male with a seven-pack-year smoking history was diagnosed with metastatic lung adenocarcinoma with bone, nodal and lung metastases. An EGFR mutation (exon 19 deletion) was identified. He commenced erlotinib, an EGFR inhibitor, at the standard dose of 150 mg daily.

After two months, he developed a grade two acneiform rash affecting his face, upper torso and limbs, attributable to erlotinib. He was prescribed topical hydrocortisone, oral minocycline (50 mg daily) and, briefly, topical clindamycin. After four months, the rash persisted. Minocycline was uptitrated to 100 mg daily with good effect. Serial CT/PET imaging showed complete metabolic response of his lung cancer to erlotinib.



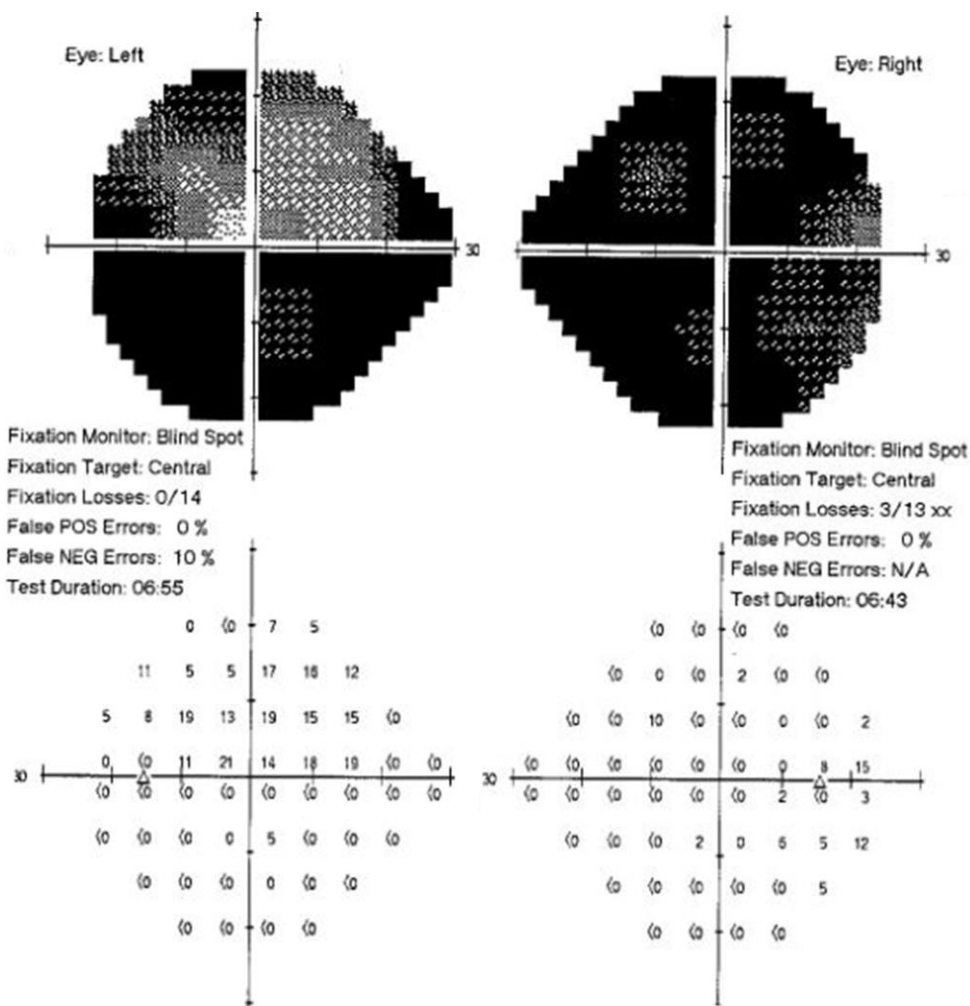
**Figure 1** Bilateral retinal photographs. Upper images (pre-decompression): severe papilloedema with peri-papillary haemorrhages. Lower images (post-decompression): bilateral optic atrophy.

After six months, his condition unexpectedly deteriorated. He developed morning headaches and episodes of disequilibrium, scalp formication, neck tightness and pulsatile tinnitus. There were conscious collapse events. Neurologic examination was unremarkable, except for fundoscopy which revealed severe bilateral papilloedema and peri-papillary haemorrhages (Figure 1).

Repeated MRI brain scans failed to detect any mass lesion, leptomeningeal enhancement or hydrocephalus. Lumbar puncture (LP) returned a marginally elevated opening pressure of 25 cmH<sub>2</sub>O. Malignant cells were present on cytology, consistent with leptomeningeal carcinomatosis.

Following multidisciplinary review, erlotinib was changed to a pulsed regimen of 1500 mg weekly to improve cerebrospinal fluid (CSF) penetration. Minocycline was ceased. Oral acetazolamide, frusemide and topiramate were unsuccessfully trialled.

Visual acuity (6/12 bilaterally) and colour vision (3/7 Ishihara plates bilaterally) continued to deteriorate. Repeat MRI brain and LP were unchanged, with malignant cells present in the CSF but no abnormality seen on MRI. However, neurosurgical insertion of Codman manometer revealed an actual opening pressure of 70 cmH<sub>2</sub>O, and monitoring pressures approximating 40 cmH<sub>2</sub>O.



**Figure 2** Visual field deficits.

Insertion of a ventriculoperitoneal (VP) shunt immediately improved his symptoms of intracranial hypertension. However, post-papilloedema optic nerve atrophy resulted in a final visual acuity of 6/36

OS and 6/9 OD with extensive visual field loss (Figure 2). He remained otherwise well but later succumbed to progressive cancer two years four months post shunt insertion.

## Discussion

Intracranial hypertension in our patient was a consequence of prolonged minocycline use and/or leptomeningeal carcinomatosis.

Tetracycline antibiotics have been reported in case series to cause intracranial hypertension [6-13]. A postulated mechanism is interference with energy dependent uptake pathways in the arachnoid granulations, restricting CSF absorption [7]. Some individuals may be genetically predisposed to this effect [10]. Despite their widespread use for erlotinib rash, to our knowledge, this is the first report of tetracycline-related intracranial hypertension when used for this indication.

Most patients experience improvement after drug cessation. However, despite the short half-life of these agents, recovery often takes several months and may be incomplete [11, 13]. Prompt recognition and aggressive management is therefore crucial. Supportive therapies to alleviate intracranial hypertension include carbonic anhydrase inhibitors, loop diuretics and topiramate, which act by reducing CSF production rate. Neurosurgical decompression is necessary in fulminant or refractory cases [14, 15].

Opening pressures on LP in our patient were only slightly elevated, however central monitoring demonstrated severe intracranial hypertension. LP opening pressures are generally representative of pressure in all CSF spaces [16]. However, this measure can be notoriously unreliable, especially in the setting of altered CSF dynamics [17, 18]. Furthermore, CSF pressures are dynamic and single readings may miss elevations if performed between pressure waves [19, 20].

In this case, vision loss progressed despite misleadingly normal investigations, emphasising the importance of papilloedema as a clinical sign and an indication of threat to vision.

## Conclusion

Patients with lung cancer being treated for rash with prolonged courses of tetracycline antibiotics are at increased risk of intracranial hypertension, which can be life- and sight-threatening. We highlight the importance of papilloedema as a clinical sign, and the role of continuous intracranial pressure monitoring in cases with discordant clinical findings and investigations.

## Consent

The patient was deceased at the time of manuscript preparation. As per correspondence with the editorial board, the requirement for consent has been waived.

## References

1. Rosell R, Carcereny E, Gervais R, Vergnenegre A, Massuti B, Felip E, Palmero R, Garcia-Gomez R, Pallares C, Miguel Sanchez J, Porta R, Cobo M, Garrido P, Longo F, Moran T, Insa A, De Marinis F, Corre R, Bover I, Illiano A, Dansin E, de Castro J, Milella M, Reguart N, Altavilla G, Jimenez U, Provencio M, Angel Moreno M, Terrasa J, Muñoz-Langa J, Valdivia J, Isla D, Domine M, Molinier O, Mazieres J, Baize N, Garcia-Campelo R, Robinet G, Rodriguez-Abreu D, Lopez-Vivanco G, Gebbia V, Ferrera-Delgado L, Bombaron P, Bernabe R, Bearz A, Artal A,

- Cortesi E, Rolfo C, Sanchez-Ronco M, Drozdowskyj A, Queralt C, de Aguirre I, Luis Ramirez J, Javier Sanchez J, Angel Molina M, Taron M, Paz-Ares L. Erlotinib versus standard chemotherapy as first-line treatment for European patients with advanced EGFR mutation-positive non-small-cell lung cancer (EURTAC): a multicentre, open-label, randomised phase 3 trial. *Lancet Oncol.* 2012, 13(3): 239-246
2. Zhou C, Wu Y-L, Chen G, Feng J, Liu X-Q, Wang C, Zhang S, Wang J, Zhou S, Ren S, Lu S, Zhang L, Hu C, Hu C, Luo Y, Chen L, Ye M, Huang J, Zhi X, Zhang Y, Xiu Q, Ma J, Zhang L, You C. Erlotinib versus chemotherapy as first-line treatment for patients with advanced EGFR mutation-positive non-small-cell lung cancer (OPTIMAL, CTONG-0802): a multicentre, open-label, randomised, phase 3 study. *Lancet Oncol.* 2011, 12(8): 735-742
  3. Potthoff K, Hofheinz R, Hassel JC, Volkenandt M, Lordick F, Hartmann JT, Karthaus M, Riess H, Lipp HP, Hauschild A, Trarbach T, Wollenberg A. Interdisciplinary management of EGFR-inhibitor induced skin reactions: a German expert opinion. *Ann Oncol.* 2011, 22(3): 524-535
  4. Segaert S, Van Cutsem E. Clinical signs, pathophysiology and management of skin toxicity during therapy with epidermal growth factor receptor inhibitors. *Ann Oncol.* 2005, 16(9): 1425-1433
  5. Thatcher N, Nicolson M, W Groves R, Steele J, Eaby B, Dunlop J, McPhelim J, Nijjar R, Ukachukwu I. Expert consensus on the management of erlotinib-associated cutaneous toxicity in the UK. *Oncologist.* 2009, 14(8): 840-847
  6. Bababeygy SR, Repka MX, Subramanian PS. Minocycline-associated pseudotumor cerebri with severe papilledema. *J Ophthalmol.* 2009, Article ID 203583, 5 pages
  7. Chiu AM, Chuenkongkaew WL, Cornblath WT, Trobe JD, Digre KB, Dotan SA, Musson KH, Eggenberger ER. Minocycline treatment and pseudotumor cerebri syndrome. *Am J Ophthalmol.* 1998, 126(1): 116-121
  8. Fraser CL, Biousse V, Newman NJ. Minocycline-induced fulminant intracranial hypertension. *Arch Neurol.* 2012, 69(8): 1067-1070
  9. Friedman DI, Gordon LK, Egan RA, Jacobson DM, Pomeranz H, Harrison AR, Goldhammer Y. Doxycycline and intracranial hypertension. *Neurology.* 2004, 62(12): 2297-2299
  10. Gardner K, Cox T, Digre KB. Idiopathic intracranial hypertension associated with tetracycline use in fraternal twins: case reports and review. *Neurology.* 1995, 45(1): 6-10
  11. Kesler A, Goldhammer Y, Hadayer A, Pianka P. The outcome of pseudotumor cerebri induced by tetracycline therapy. *Acta Neurol Scand.* 2004, 110(6): 408-411
  12. Lochhead J, Elston JS. Doxycycline induced intracranial hypertension. *BMJ.* 2003, 326(7390): 641-642
  13. Winn BJ, Liao YJ, Horton JC. Intracranial pressure returns to normal about a month after stopping tetracycline antibiotics. *Arch Ophthalmol.* 2007, 125(8): 1137-1138
  14. Biousse V, Bruce BB, Newman NJ. Update on the pathophysiology and management of idiopathic intracranial hypertension. *J Neurol Neurosurg Psychiatry.* 2012, 83(5): 488-494
  15. Matthews YY. Drugs used in childhood idiopathic or benign intracranial hypertension. *Arch Dis Child Educ Pract Ed.* 2008, 93(1): 19-25
  16. Lenfeldt N, Koskinen L-OD, Bergenheim AT, Malm J, Eklund A. CSF pressure assessed by lumbar puncture agrees with intracranial pressure. *Neurology.* 2007, 68(2): 155-158
  17. Smyth GE, Henderson WR. Observations on the cerebrospinal fluid pressure on simultaneous ventricular and lumbar punctures. *J Neurol Psychiatry.* 1938, 1(3): 226-238

18. Killer HE, Jaggi GP, Miller NR, Huber AR, Landolt H, Mironov A, Meyer P, Remonda L. Cerebrospinal fluid dynamics between the basal cisterns and the subarachnoid space of the optic nerve in patients with papilloedema. *Br J Ophthalmol*. 2011, 95(6): 822-827
19. Czosnyka M, Pickard JD. Monitoring and interpretation of intracranial pressure. *J Neurol Neurosurg Psychiatry*. 2004, 75(6): 813-821
20. Owler BK, Fong KCS, Czosnyka Z. Importance of ICP monitoring in the investigation of CSF circulation disorders. *Br J Neurosurg*. 2001, 15(5): 439-440