

## Case Report

# Kimura's Disease: A Rare Clinical Entity for A Head & Neck Surgeon

Ali Azim, Asad Azim, Talat Waseem\*, Kh. M. Azim  
Shalamar Medical & Dental College, Lahore, Pakistan

### Abstract

**Background:** Kimura's disease, previously known as a variant of angiolymphoid hyperplasia with eosinophilia (ALHE), is now considered a distinct clinical entity. In contrast to ALHE, it presents with exuberant systemic autoimmune response involving lymphoid system more readily and at times salivary glands. Disease typically presents with a head and neck region mass associated with peripheral eosinophilia and raised IgE levels with occasional but concurrent renal or pulmonary involvement in advanced cases. Association of this disease to allergic rhinitis has not been reported in the previous medical literature.

**Case Presentation:** Young Asian male was referred to us with suspicion of primary parotid tumor. He had typical symptom complex of allergic rhinitis with recurrent frontal and parotid region swelling associated with peripheral eosinophilia (25%) and elevated IgE levels (1703 IU/mL). FNAC of the lesions was inconclusive and hence underwent US- guided core biopsy, which revealed a diagnosis of Kimura's disease. Superficial parotidectomy and excision of frontal lesion were performed and histopathology of the lesion confirmed Kimura's disease with involvement of parotid gland. Now the patient is on oral corticosteroids and mast cell stabilizers without recurrence for last 3 months since operative intervention.

**Conclusions:** Kimura's disease rarely involves parotid gland and its association with allergic rhinitis is being reported first time in medical literature to best of our knowledge. Kimura's disease should include in the differential diagnosis of a parotid region mass.

**Keywords:** Kimura's disease; parotid gland; angiolymphoid hyperplasia with eosinophilia; ALHE

**Academic Editor:** Xiaoning Peng, Hunan Normal University School of Medicine, China

**Received:** August 12, 2014; **Accepted:** September 7, 2014; **Published:** September 22, 2014

**Competing Interests:** The authors have declared that no competing interests exist.

**Consent:** We confirm that family members of the patients have given their informed consents for the case report to be published.

**Copyright:** 2014 Waseem T *et al.* This is an open-access article distributed under the terms of the Creative Commons Attribution License, which permits unrestricted use, distribution, and reproduction in any medium, provided the original author and source are credited.

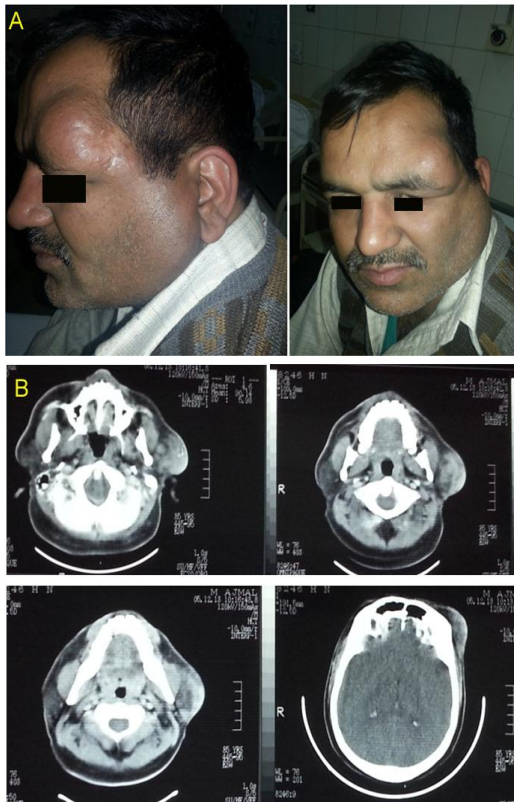
\***Correspondence to:** Talat Waseem, Shalamar Medical & Dental College, Lahore, Pakistan; Email: [twaseem@gmail.com](mailto:twaseem@gmail.com)

## Background

Kimura's disease (KD) is an uncommon chronic inflammatory disorder of obscure etiology [1-6]. Role of fungi, toxins, parasites and viruses in induction of this immunological disorder has been suggested; however lacks convincing scientific evidence [1,2,5]. Secondary to ill-defined insult

helper T cell 2 (Th2) mediated autoimmune response, eosinophilia, raised IgE levels resulting in a head and neck region mass with or without concurrent renal and/or pulmonary involvement form basis of its diagnosis [1,2,5]. Clinically, it presents as either a solitary mass or multiple subcutaneous nodules, predominantly in

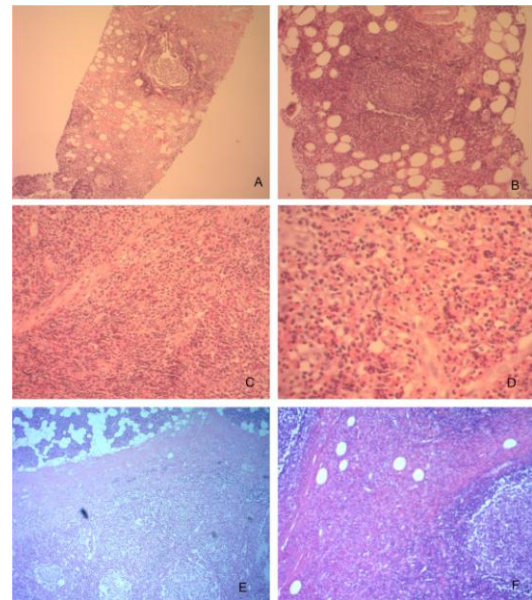
preauricular, forehead, & scalp region and rest of the diagnostic features usually reveal on further work up [1-6]. Lacrimo-orbital and upper extremity involvement although reported is a less consistent feature [1,5]. Occasionally work up for hyper-eosinophilia would indicate the diagnosis of Kimura's disease [1,5]. A head & neck surgeon is likely to encounter such a case either on work up of head & neck region mass, cervical lymphadenopathy or as a suspected primary salivary gland tumor. This patient presented to us with suspected primary parotid region tumor, which later proved as a manifestation of Kimura's disease.



**Figure 1 A**, Patient presented with recurrent swelling of the left frontal and parotid region, firm in consistency with preserved facial nerve function. **B**, CT Scan (axial sections taken through head and neck region) The lumps have hyper-dense irregular signals only involving superficial part of parotid gland and sparing deeper portion (Middle & lower panel). Hyperdense lesion is also apparent in frontal scalp (lower panel).

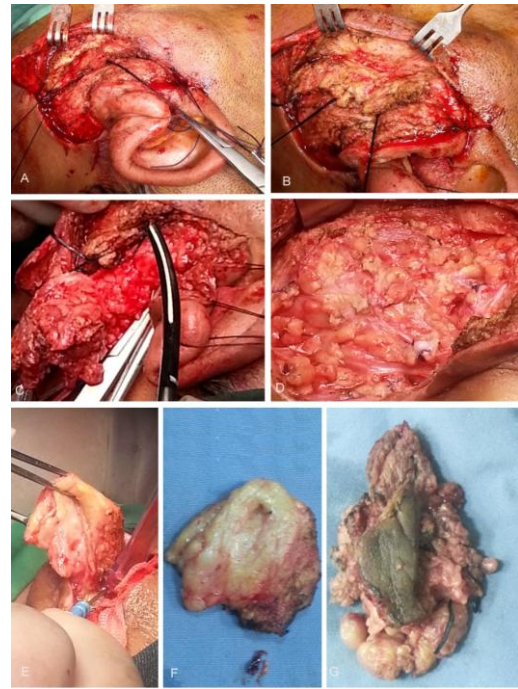

Figure 2 Patient underwent superficial parotidectomy with predictable safety of the facial nerve and its branches (A-D). Excision of frontal lesion (E) is depicted and frontal lesion (F) and parotid lesion (G) specimens have been shown.



**Figure 3** Histopathology of the resected specimens showing gross follicular germinal centers with eosinophils, thick walled venules at low (A,B), medium (C) and high resolution (D) and focal involvement of the parotid gland (E,F).

## Case Presentation

Thirty nine year old factory worker presented to us with recurrent swelling in the left frontal region and left parotid region (Figure 1A) associated with generalized pruritis, rhinorrhea, postnasal drip and occasional dry cough. He had excision of the left frontal region swelling in October 2009, which was histologically mis-reported as “dermoid cyst”. Now he presented with recurrence of the frontal swelling along with an additional swelling in left parotid region. Further work up with CT scan head & neck region showed hyperdense lesions involving the subcutaneous plane and superficial part of the left parotid gland. No significant lymphadenopathy could be appreciated (Figure 1B). Complete blood count revealed eosinophilia (25%) and markedly raised IgE levels (1703 IU/mL). Routine biochemistry and urine complete examination were entirely within physiological limits. X-ray chest did not show any reticular-nodular shadowing and pulmonary function tests were also within normal limits. Stool complete examination was negative for any parasitic infestation. Apart from routine laboratory findings, FNAC was done which was inconclusive with suspicion of a lymphoproliferative disorder. Considering diagnostic uncertainty, patient underwent US guided core biopsy to avoid unnecessary parotidectomy if it were a case of lymphoproliferative disorder. The cores of the sections revealed multiple lymphoid follicles with active germinal centers, occasional angiod component with eosinophilia and a diagnosis of Kimura’s disease was made (Figure 3- A-D). Considering resectability and the size parotid region swelling, patient underwent superficial parotidectomy with predictable safety of facial nerve and frontal lesion was also excised. The tumor was densely adherent to the skin and deeper tissues making dissection rather difficult (Figure 2). In this particular case, parotidectomy was a difficult one as the texture of tumor was more of fibrous kind densely adherent to skin and underlying parotid tissue. Fortunately we were able to achieve a plane of dissection superficial to the

facial nerve to ensure its preservation. No radiological or clinical parameter favored involvement of pulmonary parenchyma, airways or renal involvement secondary of significant eosinophilia and raised IgE levels. Histopathology was consistent with diagnosis of Kimura’s disease with focal invasion of parotid gland (Figure 3- E-F). Peritumoral lymph nodes showed reactive changes without involvement of lymph nodes themselves. Patient is currently on mast cell stabilizers, oral corticosteroids and has no recurrence for last 3 months since last operative intervention.

## Discussion & Conclusion

Despite significant controversy in the medical literature, Kimura’s disease is no longer considered a variant of ALHE and there is a developing consensus among the surgeons, physicians and pathologists that this disease should be considered and treated as a separate entity [1-6]. Pathogenesis of this disorder still remains a matter of debate [1-6]. An abnormal T cell stimulation seems possible when considering the presence of eosinophilia, elevated IgE and IL-5 levels [1,2,5,6]. Infectious agents as well as autoantibodies have not yet been identified [1,5]. However, it is thought that an unusual autoimmune response or a parasitic infection may be responsible for onset of the disease. Classically a triad of head & neck mass with characteristic histological features, eosinophilia and raised IgE levels manifesting in form of generalized pruritis, lymphadenitis and enlargement of salivary glands with or without pulmonary or renal involvement should point towards the diagnosis of Kimura’s disease [1,2,5,6]. Disease has prolonged indolent course and preferentially affects Asian males though no race is immune to it [1-5]. Parotid gland involvement is not very common, but nevertheless, may occur as in our case [8-11]. In most cases the size of the mass ranges from 1-10 cm [5]. In addition, multiple regional lymph nodes are often involved presenting as a multifocal mass [1-6]. As demonstrated in our patient, Kimura’s disease

can be accompanied by symptom complex of allergic rhinitis which may well be explainable by markedly raised IgE levels [1,5,7]. To the best of our knowledge Kimura's disease has been first time linked to allergic rhinitis. Though it frequently presents in form of head & neck region mass (76%), it appears more prudent to include this condition among immunological disorders rather an oncological one. Indeed studies have suggested involvement of activated CD4<sup>+</sup> T lymphocytes, granulocyte colony stimulating factor, tumor necrosis factor- $\alpha$ , interleukins and RANTES in the pathogenesis of Kimura's disease [1,5,6]. The renal involvement is attributed secondary to deposition of immune complexes in glomeruli [1, 5]. Fortunately our case did not exhibit any such evidence at the moment however he would be followed up in coming period for such a

development in his clinical course. Important differential diagnoses include Hodgkin's lymphoma, primary salivary gland tumor, Castleman's disease, hypereosinophilic syndrome, angiolymphoid hyperplasia with eosinophilia, which all should be excluded histologically [1-6]. The differentiation of ALHE and Kimura's disease can often be difficult. Table 1 describes the typical differences between the two entities. Histologically, besides hyperplasia, the lymph node architecture remains preserved and B and T cells are found in their normal nodal compartments [1,5]. The lymph nodes may be characterized by eosinophilic microabscesses, eosinophilic folliculolysis, (perivenular) sclerosis and eosinophilic infiltrates in the germinal centre [1,5]. Vascularisation of the germinal centre is common, but also germinal centre necrosis can be present [1,5].

**Table 1 Clinical and Histological Differences between Kimura's disease and ALHE**

	Kimura's Disease	Angiolymphoid Hyperplasia with Eosinophilia (ALHE)
<b>Clinical</b> <sup>1,5,6,7</sup>		
Gender	Male predominance (2:1) <sup>1,5</sup>	Both; Predominantly female
Ethnicity	Asian (Japan, China, Thailand) <sup>1-6</sup>	No racial preference
Age	20-40 Years	Any age
Morphology	Subcutaneous Masses	Dermal nodular swelling
Infiltration	Deeper tissues, lymph nodes, salivary glands	Superficial Dermal Involvement
Overlying Skin	Normal	Erythematous, Brown
Localization	Head & Neck preferentially (70%), groin (15%), extremities (12%) and trunk (3%) <sup>1,5,6,7</sup>	More generalized distribution
Lymphadeopathy	Common (66%) <sup>5</sup>	Rarely
Blood Eosinophilia	Marked	Mild to moderate
Serum IgE levels	Markedly raised	Mild to moderate
Glomerulonephritis	Occasional (7-20%)	Rare
Pulmonary involvement	Asthma, Löffler's syndrome; Allergic Rhinitis reported <sup>7</sup>	
<b>Histological</b> <sup>1,5</sup>		
Tissue Infiltration	Subcutaneous, Muscle, underlying tissues	Subcutaneous, dermal
Characteristics of Infiltrate	Diffuse	Nodular
Germinal Centers	More Common; Lymphoid component a dominant feature; vascularization common; microabscess formation; perifollicular fibrosis; Eosinophilic infiltration	Less Common, lymphoid component less dominant feature; angiod component more dominant feature;
Fibrosis	Marked	Mild to moderate

Eosinophilia	Massive	Mild to moderate
Blood Vessels	Well formed but angiod component is less prominent feature	Variable but angiod component is more prominent feature
Mucin	Mucin absent in blood vessels	Mucin more prominent in blood vessels
Endothelial Cytology	Occasionally atypical without vacuolization	Often atypical with vacuolization

Radiological evaluation in form of US, CT scan and MRI are helpful to assess the extent and local spread of lesion and its lymphatic spread, however they are not diagnostic [12]. It may be helpful in excluding few important differential diagnoses however [12].

A standard therapy is yet to be defined. Multiple treatment options have been used previously with varying results, including surgery, radiotherapy, cetirizine, steroid and cyclosporine therapy [1,2,6,13]. No randomized trial is reported in literature to suggest a favorable treatment option. For recurrent lesions radiotherapy has shown some promise [1, 13]. We are currently using mast cell stabilizers and corticosteroids to ensure remission and to treat rhinorrhea, postnasal drip and dry cough and patient is clinically responding to it well. For more exuberant systemic illness further immune suppression may be considered during later course of disease.

### Abbreviations

Immunoglobulin E (IgE), Angiolymphoid hyperplasia with eosinophilia (ALHE), Ultrasound (US), Computed Tomography (CT)

### Author Contribution

TW wrote the paper and made the final revision. AA collected data and reviewed the text. YA and FA designed the study, chose figures and reviewed the paper. KMA coordinated the study, performed the operation, made style and language revision. All authors read and approved the final manuscript.

### References

1. Meningaud JP, Pitak-Arnop P, Fouret P, Bertrand JC. Kimura's disease of the parotid region: report of 2 cases and review of the literature. *J Oral Maxillofac Surg*. 2007, 65:134-140
2. Arshad AR. Kimura's disease of parotid gland presenting as solitary parotid swelling. *Head Neck*. 2003, 25:754-757
3. Gao Y, Chen Y, Yu GY. Clinicopathologic study of parotid involvement in 21 cases of eosinophilic hyperplastic lymphogranuloma (Kimura's disease). *Oral Surg Oral Med Oral Pathol Oral Radiol Endod*. 2006, 102:651-658
4. Kung IT, Gibson JB, Bannatyne PM. Kimura's disease: a clinico-pathological study of 21 cases and its distinction from angiolymphoid hyperplasia with eosinophilia. *Pathology*. 1984, 16:39-44
5. Chen H, Thompson LD, Aguilera NS, Abbondanzo SL. Kimura's disease: a clinicopathologic study of 21 cases. *Am J Surg Pathol*. 2004, 28:505-513
6. Khoo BP, Chan R. Kimura's disease: 2 case reports and a literature review. *Cutis*. 2002, 70:57-61
7. Ito S, Kume H, Kimura's T, Yoshida N, Mizutani H, Ito Y, Suzuki R, Yamaki K. [Two cases of Kimura's disease associated with bronchial asthma]. *Nihon Kokyuki Gakkai Zasshi*. 1999, 37:1008-1012
8. Sah P, Kamath A, Aramanadka C, Radhakrishnan R. Kimura's disease - An unusual presentation involving subcutaneous tissue, parotid gland and lymph node. *J Oral Maxillofac Pathol*. 2013, 17:455-459
9. Bonfils P, Moya-Plana A, Badoual C, Nadéi S, Malinvaud D, Laccourreye O. Intraparotid Kimura's disease. *Eur Ann Otorhinolaryngol Head Neck Dis*. 2013, 130:87-89

10. Uysal IO, Eryilmaz MA, Salk I, Abasiyanik F. Kimura's disease in the parotid gland. *J Craniofac Surg.* 2011, 22:337-338
11. Dik VK, van de Wiel BA, Vasmel WL. Kimura's's disease of the parotid glands and multiple cervical lymph nodes. *Neth J Med.* 2010, 68:175-177
12. Park SW, Kim HJ, Sung KJ, Lee JH, Park IS. Kimura's disease: CT and MR imaging findings. *AJNR Am J Neuroradiol.* 2012, 33:784-788
13. Sato S, Kawashima H, Kuboshima S, Watanabe K, Kashiwagi Y, Takekuma K, Hoshika A. Combined treatment of steroids and cyclosporine in Kimura's disease. *Pediatrics.* 2006, 118:e921-e923