

Case Report

Therapy Related Chronic Myeloid Leukemia (trCML) or non-Therapy Related Second Malignancy Chronic Myeloid Leukemia (smCML) following Diffuse Large B-Cell Lymphoma(DLBCL): A Case Report and Review of Literature

Robert Louis^{1*}, Sunil Kumar Gupta¹, Sonal Jain²,
Anurag Mehta², and Mohit Agarwal¹

¹ Department of Medical Oncology Unit II, Rajiv Gandhi Cancer Institute and Research Centre, New Delhi, India

² Department of Lab Services & Pathology, Rajiv Gandhi Cancer Institute and Research Centre, New Delhi, India

Abstract

Introduction: Second malignancy could be either previous therapy related or non-therapy related like syndromic or shared etiologic exposure. It could be either a hematological/solid malignancy following treatment for previous solid tumour or prior hematological malignancy. Review of literature regarding secondary Chronic Myeloid Leukemia (CML) following previous active treatment for primary cancer is listed out for further understanding.

Presentation of Case: We describe a 71 year old elderly male who developed Chronic Myeloid Leukemia(CML) after a period of 6 years during follow up of Stage IV Diffuse Large B-Cell Lymphoma(DLBCL) for which he received 8 cycles of R-CHOP based Chemo-immunotherapy in 2008. Whether it is therapy related Chronic Myeloid Leukemia (trCML) following prior cytotoxic treatment or simply a non-therapy related second malignancy Chronic Myeloid Leukemia(smCML) is a matter of debate. However our patient responded dramatically like de novo CML to imatinib therapy.

Conclusion: Therapy related CML or non therapy related second malignancy CML following DLBCL treatment is rare but responds dramatically like de novo CML to imatinib therapy.

Keywords: Therapy-related CML; Second malignancy CML; CML following DLBCL treatment

Academic Editor: Xiaoning Peng, Hunan Normal University School of Medicine, China

Received: November 18, 2015; **Accepted:** March 9, 2016; **Published:** April *, 2016

Competing Interests: The authors have declared that no competing interests exist.

Consent: Consent was taken from the patient for publication of this case report.

Copyright: 2016 Louis R *et al.* This is an open-access article distributed under the terms of the Creative Commons Attribution License, which permits unrestricted use, distribution, and reproduction in any medium, provided the original author and source are credited.

***Correspondence to:** A. Robert Louis, Department of Medical Oncology Unit II, Rajiv Gandhi Cancer Institute and Research Centre, New Delhi, India

E-mail: drrobertlouis@gmail.com

Introduction

Second malignancy could be either previous therapy related or non-therapy related like syndromic or shared etiologic exposure. It could be either a hematological/solid malignancy following treatment for previous solid tumour or prior hematological malignancy. Review of literature regarding secondary Chronic Myeloid Leukemia (CML) following previous active treatment for primary cancer is listed out for further understanding.

Case Presentation

Seventy one year old male was diagnosed with Diffuse Large B-Cell Lymphoma(DLBCL,Stage IV A) in 2008 (Figure 1)and subsequently treated with 8 cycles of R CHOP . He attained complete metabolic remission and was on regular follow up on outpatient basis. He was completely asymptomatic and his Total leukocyte count(TLC) rose from 18,000/cumm in May 2014 to 87,400/cumm in Aug 2014. The Peripheral smear(Figure 2) showed marked leucocytosis with shift to left with preponderance of myeloid precursors with peak in neutrophil lineage with basophilia (DLC : My-21, MMy-11, N-51,L-05,M-03, E-04,B-05) . A Bone marrow aspirate and Bone marrow biopsy examination along with testing for Bcr/Abl rearrangement was advised. However, he defaulted briefly and returned again with weakness & easy fatigability and TLC of 2,15,700/cumm in may 2015 with a Differential Count as follows (DLC-BI-02, My-40, MMy-12,N-40, L-02, M-01, E-01, B-02). Clinical examination revealed no palpable lymphadenopathy or hepatosplenomegaly. RT-PCR for Bcr/Abl rearrangement was done and was positive (Figure 3) . CT scan evaluation showed no evidence of lymphoma involvement. A diagnosis of therapy related Chronic Myeloid Leukemia (trCML) or non-therapy related second malignancy Chronic Myeloid Leukemia (smCML) following DLBCL has been made and started on Imatinib 400 mg once daily with adequate hydration and tumour lysis prophylaxis. He improved dramatically and his last TLC count after one month of imatinib therapy has reduced to 24,000 with marked improvement in weakness and fatigue.

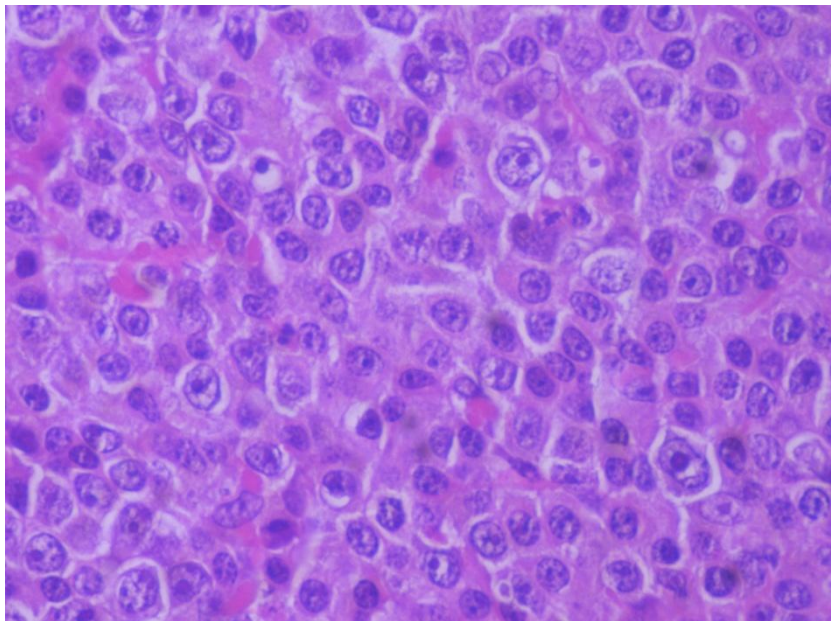


Figure 1 Biopsy of Lymph node showing large monomorphic cells with prominent nucleoli suggestive of Diffuse Large Cell Lymphoma (400X)

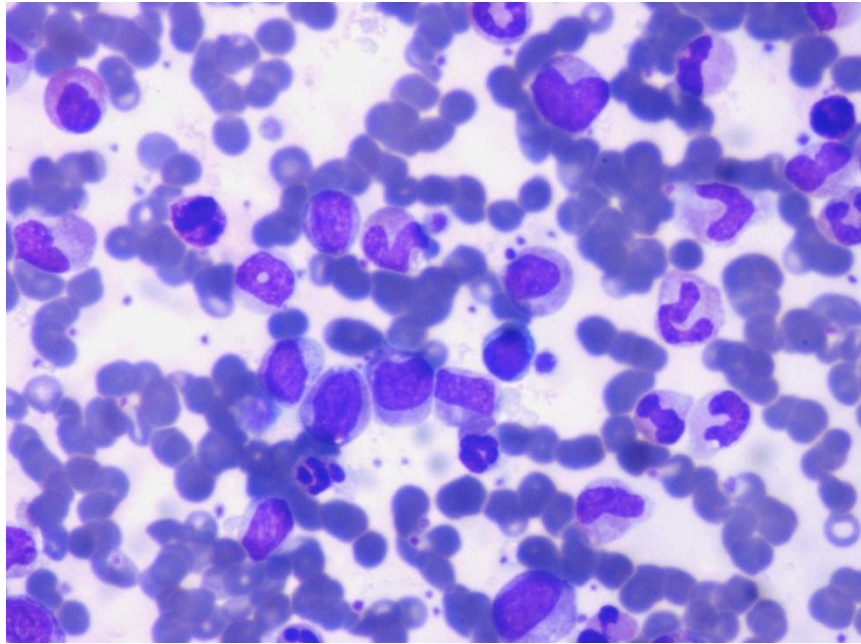


Figure 2 Peripheral smear picture showing left shift in myeloid series with basophils suggestive of Chronic Myeloid Leukemia

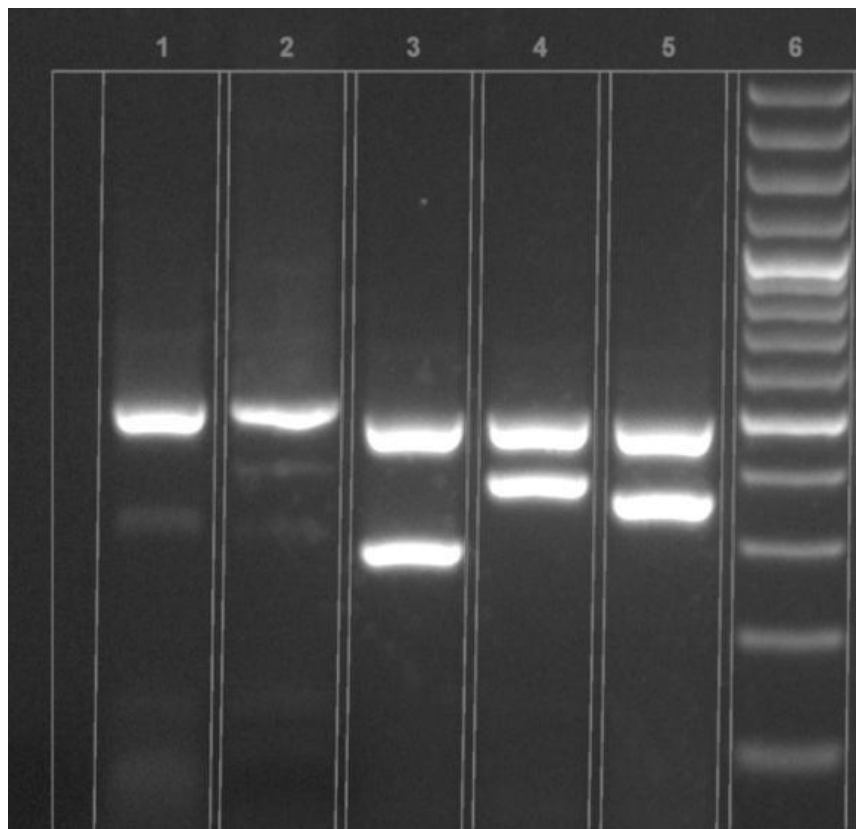


Figure 3 Agarose Gel Detection of Bcr/Abl :Lane1- normal control, Lane 3 patient – Mbc, Lane 4, 5 - +ve control, Lane 6 – 100bp molecular ladder, E1a2 – 381bp, E13a2 – 285bp, E14a2 – 360bp

Discussion

Non-Hodgkins Lymphoma(NHL) patients have a significant increased risk of developing second primary cancers. Second malignancy following non-Hodgkins lymphoma(NHL) therapy can be either therapy related or non-therapy related. Therapy related factors include previous chemotherapy(Topoisomerase inhibitors, alkylationg agents etc), Radiation therapy or combined modality treatment. Factors such as better survival following previous effective treatment, increasing age, genetic susceptibility, viral infections, tobacco use or immunologic alteration are possible reasons for non-therapy related second malignancy[1-3]. The risk of second cancer after NHL increases as much as 47% and the incidence ratio increases with age with the cumlulative incidence of 8.2% at 15 years [4,5]. The pooled Relative Risk of second malignant neoplasms after NHL therapy is increased than general population and the risk impact differs for various treatment modalities [6]. Therapy related second primary cancer increases with every decade since NHL diagnosis with relatively excess risk observed in older patients [7,8]. The pattern of second malignancy differs by NHL subtype. Both hematological and solid malignancy has been documented after NHL therapy. Treatment related malignancy following NHL therapy include cancer of lung, bladder, stomach, myeloid leukemia and hodgkins lymphoma. While the Standardised Incidence Ratio(SIR) of acute non-lymphocytic leukemia(SIR 4.96 & 5.96) is increased enormously after Diffuse large B Cell Lymphoma (DLBCL) and Follicular Lymphoma(FL) treatment, Chronic Myeloid Leukemia(SIR 2.5 vs 0.9 & 1.75) risk is elevated after DLBCL as compared with Chronic Lymphocytic Leukemia/Small Lymphocytic Leukemia and Follicular Lymphoma treatment($P < 0.5$) [9]. Around 150 cases of therapy related or second malignancy CML has been described in literature post treatment of solid or Lymphoid malignancies(Table 1).The median duration in development of trCML is 4 years(range 5 months to 14 years).Therapy related CML has been described after the receipt of chemotherapy or Radiotherapy alone or after combined modality treatment.Prior therapy for hematolymphoid malignancies for low grade NHL (like CLL, follicular lymphoma, waldenstroms macroglobulinemia) and high grade NHL(like DLBCL) included treatment with chlorambucil to Rituximab based immunochemotherapy with or without Radiotherapy [10-26]. Therapy for solid tumours with histologic specific chemotherapy schedules (including oxaliplatin, irinotecan, 5Flurouracil based therapy for colorectal cancer[27-31] and anthracyclin based chemotherapy for breast cancer) and Radiation therapy for solid tumours (like cancer cervix, breast cancer, rectal cancer) [32-35] as a part of multimodality treatment has caused trCML. Radioactive therapy with ¹³¹I for thyroid cancer has also been implicated in therapy related CML [36-38]. Recently more cases of treatment related CML has been noted after using S1 chemotherapy especially when given for prolonged time(typically 1 or 2 yrs) as in Japan where S1 is being used increasingly in many solid tumours in adjuvant or metastatic setting [39-44]. Two patient had unusual synchronus presentation of CML with Gastrointestinal Stromal tumour diagnosis which has been treated with imatinib, the standard treatment for both the condition with good outcome [45]. Treatment related CML or non therapy related second malignant CML cannot be distinguished from denova CML cytogenitically. Treatment related CML is more increasingly recognised than non-therapy related second malignant CML because of increasingly aggressive therapy for primary malignancy although there is no better objective way to identify the nature of them. Non therapy related Second malignant CML tend to increase with increasing age at onset of first primary and is a rare entity [13,14]. However both therapy related or non-therapy related CML respond favourably to imatinib therapy and behave similar to denova CML [21,22].

Secondary CML following DLBCL has been reported recently in 4 case reports where it was noted

to occur from 9 months to 10 year post DLBCL treatment with CHOP based chemotherapy plus or minus rituximab /Radiotherapy [10,12,15,19]. One case diagnosed CML synchronously with NHL relapse which was treated with combination of rituximab and Imatinib [18].

Table 1 Table showing published Case reports/Series of therapy related or second malignancy CML following treatment of primary hematolymphoid or solid tumours.

Author	Primary Cancer	Treatment	Number of patients	Duration since primary treatment	Reference
Demiriz IŞ	DLBCL	R CHOP	1	5 years	10
Shibazaki M	Follicular Lymphoma	Chemotherapy(RFM Protocol)	1	3 years	11
Lee HY	DLBCL	Chemotherapy(CHOP)+Radiation	1	10 years	12
Aguiar RC	Both solid and hematological(5 CLL,2 NHL)	Chemotherapy	32	-	13
Specchia G	Both solid and hematological	-	9+77(therapy related)	-	14
Zahra K	DLBCL in a child	Chemotherapy	1	9 months	15
Alsop S	ALK +ALCL	Chemotherapy	1	4 years	16
Bolaños-Meade	Lymphoid	Chemotherapy	1	7 years	17
Breccia M	NHL	chemotherapy	1	-	18
Hsiao HH	Lymphoma(High grade MALT)	Chemotherapy+PBSCT	1	10 months	19
Wandroo FA	Hairy cell leukemia	deoxycoformycin	1	4 years	20
Ramanarayanan J	Lymphoid malignancies(HL,NHL,CLL)	Chemotherapy	3	8,10,2.5 years respectively	21
Waldman D	NHL,Nasopharynx	Chemotherapy,Radiation	2	-	22
Verhoef GE	Hodgkins lymphoma	Chemotherapy	1	8 years	23
Cazzola M	NHL	Chemotherapy+Radiotherapy	1	-	24
Ragupathi L	Multiple myeloma	Steroids	1	1.5 years	25
Majado MJ	Waldenstrms macroglobulinemia	Chlorambucil	1	3 years	26
Gokel Y	Colon adenocarcinoma	Chemotherapy(cisplatin+5FU)	1	-	27
Vakili-Sadeghi M	Rectosigmoid	Oxaliplatin +5FU	1	2 years	28
Kadikoylu G	Rectal adenocarcinoma	Chemotherapy(Oxaliplatin,5	1	3 years	29

		FU,Irinotecan)			
Buxhofer-Ausch	Metastatic colorectal cancer	Chemotherapy(FOLFIRI +Cetuximab)	1	1 year	30
V					
Manabe M	Rectal cancer	S1 therapy(1 year)	1	3 years	31
Pavithran K	Papillary thyroid caner	Radioactive iodine 131	1	14 years	32
Wang KL	Papillary thyroid cancer	Radioactive iodine 131	1	13 years	33
Walgraeve D	Thyroid cancer	Radioactive iodine 131	1	-	34
Shimon I	Papillary & Follicular	Radioactive iodine 131	2	4 & 10 years	35
Porta C	Breast cancer	Chemotherapy	1	-	36
Bauduer F	Breast,cervix	Radiotherapy	3	1-25 years	37
Abu-Ghanem S	Breast cancer	Chemotherapy	2	1 year	38
Tsuzuki M	Gastric cancer	5'-deoxy-5-fluorouridine	1	6 years	39
Higuchi M	Gastric cancer	T-S1 therapy(21 months)	1	3 years	40
Waller CF	Small cell lung cancer	High dose	1	2 years	41
		chemotherapy+autoSCT+Radiotherapy			
Noda M	Pineal germinoma	Chemotherapy+Radiation	1	4 years	42
Numata A	Ewings sarcoma	Autologous stem cell transplant	1	4 years	43
Langabeer SE	Prostate cancer	Radiotherapy	1	5 months	44
				post RT	
Sakamoto E	GIST	Imatinib	2	synchronous	45
Present Case	DLBCL	R-CHOP	1	6 years	-

Conclusion

In our patient, the secondary CML is believed to be either treatment related or non therapy related. The fact he has received prior rituximab and anthracycline based therapy and no clinically palpable or enlarged splenomegaly by imaging may point to therapy related CML. The older age at onset of primary NHL and development of CML after 6 years of follow up may indicate non therapy related secondary CML, although such factors and other unknown factors in play cannot be identified clinically to distinguish accurately between the two. Therapy related CML or non therapy related second malignancy CML following DLBCL treatment is rare but responds dramatically like denova CML to imatinib therapy.

Consent

We conform Informed written consent from the patient has been obtained for the purpose f publication of case report.

References

1. Boice JD, Jr, Storm HH, Curtis RE, Jensen OM, Kleinerman RA, Jensen HS. et al., Introduction to the study of multiple primary cancers National Cancer Institute Monograph No 68 – Multiple Primary Cancers in Connecticut and Denmark 1985NIH Publication: Bethesda; 3-9.9 NCI (ed) pp
2. Travis LB, Curtis RE, Boice JD Jr, Hankey BF, Fraumeni JF Jr. Second cancers following non-Hodgkin's lymphoma. *Cancer*. 1991, 67(7):2002-2009
3. Tward JD, Wendland MM, Shrieve DC, Szabo A, Gaffney DK. The risk of secondary malignancies over 30 years after the treatment of non-Hodgkin lymphoma. *Cancer*. 2006, 107(1):108-115
4. Brennan P, Scádo G, Hemminki K, Mellekjær L, Tracey E, Andersen A et al. Second primary cancers among 109 000 cases of non-Hodgkin's lymphoma. *British Journal of Cancer*. 2005 93(1), 159-166
5. Bari A, Marcheselli L, Marcheselli R, Liardo EV, Pozzi S, Ferri P et al. Therapy-Related Myeloid Neoplasm in Non-Hodgkin Lymphoma Survivors. *Mediterranean Journal of Hematology and Infectious Diseases*. 2011, 3(1): e2011065
6. Pirani M, Marcheselli R, Marcheselli L, Bari A, Federico M, Sacchi S. Risk for second malignancies in non-Hodgkin's lymphoma survivors: a meta-analysis. *Ann Oncol*. 2011, 22(8):1845-1858
7. Hemminki K, Lenner P, Sundquist J, Bermejo JL. Risk of subsequent solid tumors after non-Hodgkin's lymphoma: effect of diagnostic age and time since diagnosis. *J Clin Oncol*. 2008, 26(11):1850-1857
8. Lorenzo Bermejo J, Pukkala E, Johannesen TB, Sundquist J, Hemminki K. Age-time risk patterns of solid cancers in 60901 non-Hodgkin lymphoma survivors from Finland, Norway and Sweden. *Br J Haematol*. 164(5):675-683
9. Lindsay M, Morton, Rochelle E, Curtis, Martha S, Linet et al. Second Malignancy Risks After Non-Hodgkin's Lymphoma and Chronic Lymphocytic Leukemia: Differences by Lymphoma Subtype. *J Clin Oncol*. 2010, 28(33): 4935-4944
10. Demiriz IŞ, Tekgündüz E, Bozdağ SC, Altuntaş F. Chronic myeloid leukemia as a secondary malignancy following treatment of diffuse large B-cell lymphoma. *Turk J Haematol*. 2014, 31(1):92-84
- Shibasaki M, Sumi M, Takeda W, Kirihara T, Kurihara T, Sato K et al. Therapy-related chronic myelogenous leukemia following RFM therapy in a patient with follicular lymphoma. *Rinsho Ketsueki*. 2014, 55(8):970-974
12. Lee HY, Lee KH, Hyun MS, Kim MK, Koh SA, Cho HS. Chronic myeloid leukemia as a secondary malignancy after diffuse large B-cell lymphoma. *Korean J Intern Med*. 2014, 29(2):250-252
13. Aguiar RC. Therapy-related chronic myeloid leukemia: an epidemiological, clinical and pathogenetic appraisal. *Leuk Lymphoma*. 1998, 29(1-2):17-26
14. Specchia G, Buquicchio C, Albano F, Liso A, Pannunzio A, Mestice A et al. Non-treatment-related chronic myeloid leukemia as a second malignancy. *Leuk Res*. 2004, 28(2):115-119
15. Zahra K, Ben Fredj W, Ben Youssef Y, Zaghouani H, Chebchoub I, Zaier M et al. Chronic myeloid leukemia as a secondary malignancy after lymphoma in a child. A case report and review of the literature. *Onkologie*. 2012, 35(11):690-693
16. Alsop S, Sanger WG, Elenitoba-Johnson KS, Lim MS. Chronic myeloid leukemia as a secondary

- malignancy after ALK-positive anaplastic large cell lymphoma. *Hum Pathol.* 2007, 38(10):1576-1580
17. Bolaños-Meade J, Sarkodee-Adoo C, Khanwani SL. CML after treatment for lymphoid malignancy: Therapy-related CML or coincidence? *Am J Hematol.* 2002, 71(2):139
 18. Breccia M, Martelli M, Cannella L, Russo E, Finolezzi E, Stefanizzi C et al. Rituximab associated to imatinib for coexisting therapy-related chronic myeloid leukaemia and relapsed non-Hodgkin lymphoma. *Leuk Res.* 2008, 32(2):353-355
 19. Hsiao HH, Liu TC, Chang CS, Sue YC, Chen TP, Lin SF. Secondary chronic myelogenous leukemia after autologous peripheral blood stem cell transplantation for lymphoma. *Int J Hematol.* 2001, 73(1):126-128
 20. Wandroo FA, Bareford D, el-Jehani F. Chronic myeloid leukaemia occurring in a patient with hairy cell leukaemia. *J Clin Pathol.* 2000, 53(12):940-941
 21. Ramanarayanan J, Dunford LM, Baer MR, Sait SN, Lawrence W, McCarthy PL. Chronic myeloid leukemia after treatment of lymphoid malignancies: response to imatinib mesylate and favorable outcomes in three patients. *Leuk Res.* 2006, 30(6):701-705
 22. Waldman D, Weintraub M, Freeman A, Neumann Y, Rechavi G, Toren A. Favorable early response of secondary chronic myeloid leukemia to imatinib. *Am J Hematol.* 2004, 75(4):217-219
 23. Verhoef GE, Demuyneck H, Stul MS, Cassiman JJ, Mecucci C, Van Den Berghe H et al. Philadelphia chromosome-positive chronic myelogenous leukemia in treated Hodgkin's disease. *Cancer Genet Cytogenet.* 1990, 49(2):171-176
 24. Cazzola M, Bergamaschi G, Melazzini M, Ponchio L, Rosti V, Molinari E. Chronic myelogenous leukemia following radiotherapy and chemotherapy for non-Hodgkin lymphoma. *Haematologica.* 1990, 75(5):477-479
 25. Ragupathi L, Najfeld V, Chari A, Petersen B, Jagannath S, Mascarenhas J. A case report of chronic myelogenous leukemia in a patient with multiple myeloma and a review of the literature. *Clin Lymphoma Myeloma Leuk.* 2013, 13(2):175-179
 26. Majado MJ, González García C, Marín-Blázquez MD, Morales Lázaro A, Moreno Moreno M. Appearance of a chronic myeloid leukemia in Waldenström's macroglobulinemia. *Sangre (Barc).* 1992, 37(6):465-466
 27. Gokel Y, Paydas S. Chronic myeloid leukemia in a patient with colon adenocarcinoma. *Haematologia (Budap).* 2002, 32(4):501-503
 28. Vakili-Sadeghi M, Omranpour M. Chronic myeloid leukemia following colon cancer treatment: A case report and literature review. *Caspian J Intern Med.* 2013, 4(3):739-742
 29. Kadikoylu G, Yavasoglu I, Barutca S, Meydan N, Bolaman Z. Chronic myeloid leukemia following the treatment of rectal adenocarcinoma. *Med Oncol.* 2008, 25(4):467-470
 30. Buxhofer-Ausch V, Hinterberger-Fischer M, Hinterberger W. Bcr-abl positive blast crisis of chronic myeloid leukemia emerging in a case of metastatic colorectal cancer 3 months after completion of an 8-month course of cetuximab and irinotecan. *Eur J Haematol.* 2006, 76(5):447-448
 31. Manabe M, Nishii T, Okita J, Nagasaki J, Harada N, Aoyama Y, Kumura T, Ohta T, Furukawa Y, Takeuchi K, Mugitani A. Chronic myelogenous leukemia after postoperative adjuvant S-1 therapy for rectal cancer: a case report. *Am J Blood Res.* 2013, 3(4):286-289
 32. Pavithran K, Doval DC. Chronic myeloid leukemia in a man with papillary carcinoma of the thyroid treated with radioactive iodine. *Am J Clin Oncol.* 2005, 28(2):216

33. Wang KL, Lin LY, Chen PM, Lin HD. Chronic myeloid leukemia after treatment with 131I for thyroid carcinoma. *J Chin Med Assoc.* 2005, 68(5):230-233
34. Walgraeve D, Verhoef G, Stul M, Cassiman JJ, Mecucci C, Van den Berghe H et al. Chronic myelogenous leukemia after treatment with 131I for thyroid carcinoma. Report of a case and review of the literature. *Cancer Genet Cytogenet.* 1991, 55(2):217-224
35. Shimon I, Kneller A, Olchovsky D. Chronic myeloid leukaemia following 131I treatment for thyroid carcinoma: a report of two cases and review of the literature. *Clin Endocrinol (Oxf).* 1995, 43(5):651-654
36. Porta C, Casagrande I, Semino G, Moroni M, Ratto C. Chronic myeloid leukemia following cyclophosphamide-containing chemotherapy in a breast cancer patient. *Haematologica.* 1993, 78(1):56-57
37. Bauduer F, Ducout L, Dastugue N, Marolleau JP. Chronic myeloid leukemia as a secondary neoplasm after anti-cancer radiotherapy: a report of three cases and a brief review of the literature. *Leuk Lymphoma.* 2002, 43(5):1057-1060
38. Abu-Ghanem S, Rabinovich A, Delgado B, Benharroch D, Ariad S, Levi I et al., Chronic myelogenous leukemia diagnosed in two patients with breast cancer. *Leuk Lymphoma.* 2011, 52(12):2399-2401
39. Tsuzuki M, Handa K, Yamamoto K, Hasegawa A, Yamamoto Y, Watanabe M et al., Chronic myeloid leukemia following chemotherapy with 5'-deoxy-5-fluorouridine for gastric cancer. *Intern Med.* 2008, 47(19):1739-1741
40. Higuchi M, Nishinaka H, Yamano Y. A case of chronic myeloid leukemia following TS-1 therapy for advanced gastric cancer. *Gan To Kagaku Ryoho.* 2006, 33(13):2049-2052
41. Waller CF, Fetscher S, Lange W. Secondary chronic myelogenous leukemia after chemotherapy followed by adjuvant radiotherapy for small cell lung cancer. *Leuk Res.* 1999, 23(10):961-964
42. Noda M, Shoda T, Takimoto Y, Okita H. Chronic myelogenous leukemia following therapy for pineal germinoma. *Rinsho Ketsueki.* 2004, 45(1):72-74
43. Numata A, Shimoda K, Gondo H, Kato K, Aoki K, Ito Y et al. Therapy-related chronic myelogenous leukaemia following autologous stem cell transplantation for Ewing's sarcoma. *Br J Haematol.* 2002, 117(3):613-616
44. Langabeer SE, Burke A, McCarron SL, Kelly J, Carroll P, Browne PV, Conneally E. Chronic myeloid leukaemia presenting post-radiotherapy for prostate cancer: further evidence for an immunosurveillance effect. *Br J Haematol.* 2013, 162(5):708-710
45. Sakamoto E, Sawada T, Osugi H, Nakamae H, Koh KR, Yamane T et al. Chronic myeloid leukemia in two patients with gastrointestinal stromal tumor. *Int J Hematol.* 2008, 88(3):348-350