

Case Report

A Case of Cervical Ectopic Pregnancy: Management and Review of the Literature

Mine Genc¹, Berhan Genc², Sefa Kurt³, Aynur Solak²

¹ Department of Obstetric and Gynecology, Sifa University School of Medicine, İzmir, Turkey

² Department of Radiology, Sifa University School of Medicine, İzmir, Turkey

³ Department of Obstetrics and Gynecology, Egean Maternity and Women's Health Training Hospital, İzmir, Turkey

Abstract

Introduction: Cervical ectopic pregnancy is a rare type of ectopic pregnancy. It can be diagnosed by transvaginal ultrasonography at an early stage and confirmed by magnetic resonance imaging.

Presentation of case: In such cases, early diagnosis and management can avert life-threatening consequences like uterine rupture and abundant hemorrhage, while sparing fertility. We herein discussed diagnostic process, follow-up, and management of a cervical ectopic pregnancy case.

Conclusion: Cervical ectopic pregnancy has been shown that the conservative methods are safe and reliable treatment techniques in early detected cervical ectopic pregnancy cases; they also have the advantage to spare future fertility of patients.

Keywords: methotrexate; cervical ectopic pregnancy; transvaginal ultrasonography

Academic Editor: Xiaoning Peng, Hunan Normal University School of Medicine, China

Received: June 15, 2014; **Accepted:** September 7, 2014; **Published:** September 13, 2014

Competing Interests: The authors have declared that no competing interests exist.

Consent: We confirm that the patient has given their informed consent for the case report to be published.

Copyright: 2014 Genc M *et al.* This is an open-access article distributed under the terms of the Creative Commons Attribution License, which permits unrestricted use, distribution, and reproduction in any medium, provided the original author and source are credited.

***Correspondence to:** Mine Genc, Department of Obstetric and Gynecology, Sifa University School of Medicine, İzmir, Turkey; Email: doktorminegenc@gmail.com

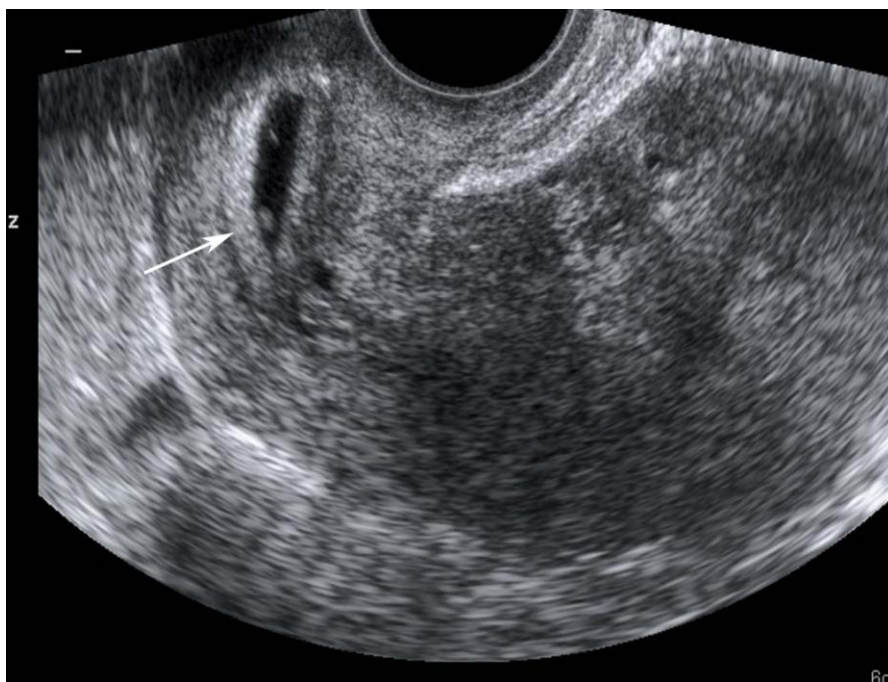
Introduction

The term ectopic pregnancy refers to a pregnancy growing outside the cavity of the womb and constitutes approximately 2% of all pregnancies. It is one of the main causes of maternal mortality and morbidity [1]. Tubal ectopic pregnancy is the most common type of ectopic pregnancy and is responsible for 95% of cases. Cervical ectopic pregnancies, on the other hand, make up 0.2% of all ectopic pregnancy cases [2]. Transvaginal ultrasonography (TVUSG) and Doppler ultrasonography are the recommended diagnostic tools for cervical ectopic pregnancies [3]. Treatment of cervical ectopic pregnancy is both life- and fertility-saving. There are fertility-saving conservative treatment options including systemic or local methotrexate (MTX), intraamniotic application of potassium chloride or hyperosmolar glucose solution, dilatation and curettage (DC), uterine artery embolisation (UAE), local resection, and operative hysteroscopy [4-6].

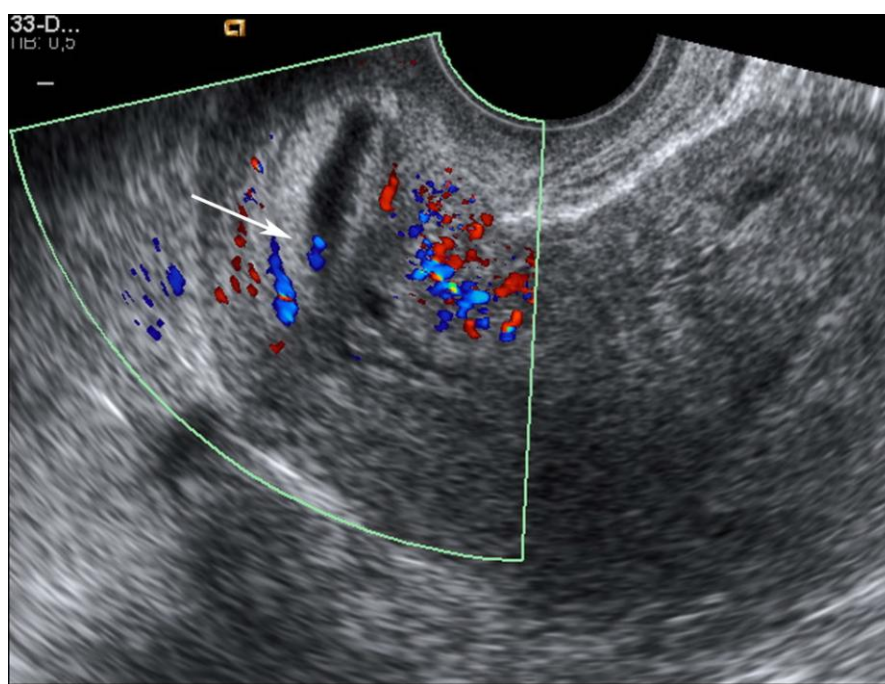
In this study, we report a case of cervical ectopic pregnancy that was diagnosed with TVUSG at an early stage and treated with systemic MTX therapy and cervical curettage.

Case report

A 35-year-old nulliparous primary infertile woman was admitted to our hospital with spontaneous early-term pregnancy, vaginal spotting, and inguinal pain. Her medical and surgical history was unremarkable. A TVUSG revealed a 6-week-old cervical gestational sac with a size of 13x14 mm, which was separate from the cervical canal and invaded anterior cervical wall (**Figure 1**). The endometrial double wall thickness was measured 18 mm. Pelvic MRI revealed a cystic formation with a diameter of 7 mm in uterine cervical region, which was compatible with a cervical gestational sac (**Figure 2**). B-HCG level was 4452 mIU/ml at the time of admission, 3415 mIU/ml the day before admission, and 2732 mIU/ml 2 days before admission. Other laboratory results were normal. The patient was recommended a conservative therapy to save fertility and MTX therapy was administered at a dose of 50 mg/m². The cervical canal was curetted two days thereafter. Around 100 ml of blood loss took place. A TVUSG examination performed 2 days after the curettage showed a normally appearing cervix. The patient was then discharged. B-HCG levels regressed and no complications occurred at follow-up.



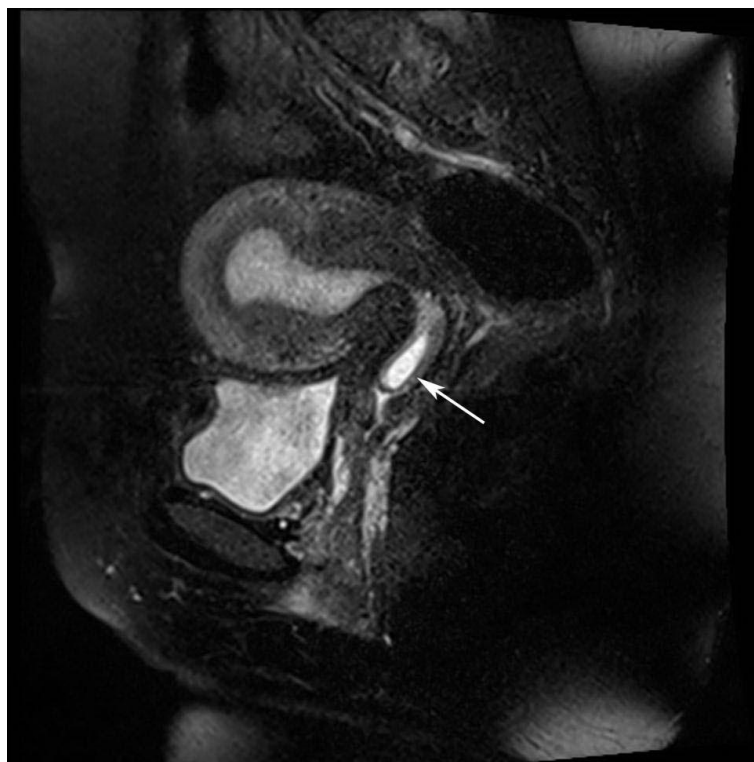
(a)



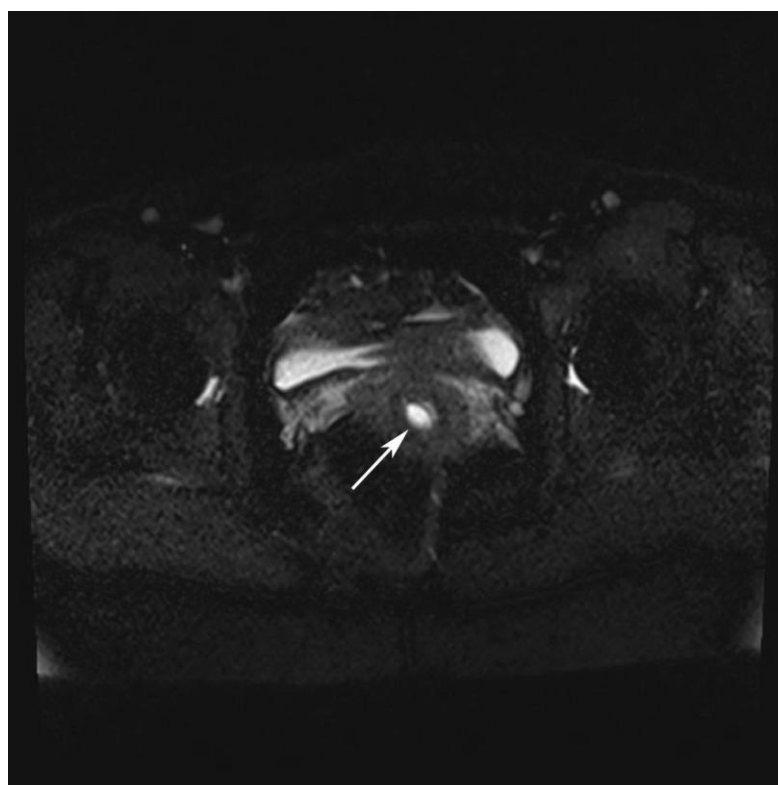
(b)

Figure 1 (a,b). Spontaneous cervical pregnancy in a 35-year-old woman. Transvaginal sonogram showing intracervical pregnancy (a). Sagittal transvaginal sonogram showing a fundal gestational sac and viable embryo (arrow)

(b).



(a)



(b)

Figure 2 (a,b). Cervical pregnancy in a 35-year-old woman. Pelvic magnetic resonance imaging sagittal (a) and axial (b) T2W images revealed a cystic formation in uterine cervical region, which was compatible with a cervical gestational sac (arrow).

Discussion

Cervical pregnancy is a rare life-threatening form of ectopic pregnancy. Clinical diagnosis of cervical ectopic pregnancy is challenging. B-HCG level may not increase as it usually would, and this was also the case in our patient. The combined approach incorporating TVUSG and Doppler ultrasonography is the gold standard for diagnosis. We made the diagnosis with TVUSG in our patient. Magnetic resonance imaging (MRI) can be used in cervical pregnancy cases that prove difficult to be diagnosed by ultrasonography [7]. However, MRI is not preferred in emergency situations since it is not readily available and cannot provide additive information above that provided by ultrasonography. In our patient, MRI was used to confirm the diagnosis owing to the fact that she had a precious pregnancy. The most common symptoms of cervical pregnancy are vaginal bleeding (91%) and inguinal pain (28%). Early-stage asymptomatic (6%) cervical pregnancies may also be detected in routine ultrasonography [8].

The etiological factors of cervical ectopic pregnancy include dilatation and curettage (the most common cause-68%), caesarean section, pregnancy via in vitro fertilization, Asherman syndrome, and history of intrauterine device use. However, the patient we reported herein had none of the above etiological factors. The cardinal USG criteria of cervical ectopic pregnancy, as defined by Ruano *et al.*, are as follows: a gestational sac in cervix, an empty uterine cavity, and a normal-sized uterus (that allows ruling out a spontaneous abortus process) [9]. In our case, TVUSG revealed a gestational sac invading anterior cervical wall, a closed cervical ostium, a thickened endometrial wall, and an empty endometrial cavity.

Women with cervical ectopic pregnancy are at high risk for life-threatening complications including uterine rupture and massive bleeding. The management of cervical ectopic pregnancies is based on the amount of bleeding, gestational age, localization of gestational sac (the localization of uterine artery at the proximal part of cervical canal is important with respect to amount of bleeding), depth of trophoblast invasion, and B-HCG level. The treatment approach for any cervical ectopic pregnancy may be either radical or conservative. Hysterectomy, which is the radical approach, is used in cases with life-threatening bleeding or with completed fertility [10].

The conservative approach may be medical or surgical [4-6]. The surgical procedures may include embolization of hypogastric or uterine artery, cervical dilatation and curettage (DC), local resection, and operative hysteroscopy. Medical treatment options include systemic or intraamniotic injection of the cytotoxic drug methotrexate, and intraamniotic injection of potassium chloride or hyperosmolar glucose. Systemic methotrexate is the standard therapy for tubal and cervical ectopic pregnancies [11].

Systemic MTX therapy may be administered as a single dose of 50mg/m² or as multiple doses of 1mg/kg (at days 1, 3, and 5) along with folinic acid (at days 2, 4, and 6). If the intraamniotic route is to be chosen, 50 mg methotrexate or 3-5 mmol/L (6-10 meq) potassium chloride can be injected [12]. While DC is a high risk procedure with respect to intraoperative hemorrhage, it can still be considered after MTX therapy under transabdominal guidance. DC may prevent risk of septic abortus and intermittent uterine bleeding. Our patient demonstrated a decline in B-HCG level after two doses of MTX therapy. We operated her with DC under transabdominal USG guidance to avert risk of septic abortus or intermittent

uterine bleeding. No postoperative bleeding occurred.

The success rate with conservative methods is 95.6% [12]. Aspiration and curettage are the most frequently used options for treatment of cervical ectopic pregnancy. The basic problem with the conservative approaches is the risk of life-threatening bleeding episodes; therefore, various techniques has been used to control bleeding after the procedure, such as placing a foley catheter as a tampon into the cervical canal, local prostaglandin injection into cervix, or placing hemostasis sutures to cervix [13]. However, these techniques may fail; in these circumstances bleeding can be stopped via surgical ligation of cervical branches of uterine artery, hysteroscopic endocervical resection during transient occlusion of iliac arteries with balloon inflation, selective uterine artery embolization, or hysterectomy [4,10,14-17].

In cervical ectopic pregnancies, the success rate of a single dose MTX is 83%, while it goes down to 54% with multiple doses of the same drug. This rate can climb up to 94% with MTX application in addition to adjuvant conservative techniques. The success rate of dilatation and curettage alone is 75% .

In conclusion, cervical ectopic pregnancy is a rare, albeit serious, form of ectopic pregnancy. It has been shown that the conservative methods are safe and reliable treatment techniques in early detected cervical ectopic pregnancy cases; they also have the advantage to spare future fertility of patients. In our case, detection of cervical ectopic pregnancy at an early stage, i.e. 6 weeks, allowed sparing fertility of our patient and prevented serious complications.

References

1. Agdi M, Tulandi T. Surgical treatment of ectopic pregnancy. *Best Pract Res Clin Obstet Gynaecol.* 2009, 23:519-527
2. Breen JL. A 21 year survey of 654 ectopic pregnancies. *Am J Obstet Gynecol.* 2002, 106: 1004- 1019
3. Pascual MA, Hereter L, Graupera B, et al. Three-dimensional power Doppler ultrasound diagnosis and conservative treatment of ectopic pregnancy in a cesarean section scar. *Fertil Steril.* 2007, 88:706.e5-e7
4. Yang JH, Shih JC, Liu KL, Yang YS. Combined treatment with temporary intraoperative balloon occlusion of common iliac arteries and hysteroscopic endocervical resection with postoperative cervical balloon for intractable cervical pregnancy in an infertile woman. *Fertil Steril.* 2007, 88:1438.e11-e13
5. Moon HS, Hyun JH, Kim KS, Kim HJ, Moon SE, Koo JS. Use of Tuohy needle for intraamniotic methotrexate injection through the cervical canal in a cervical pregnancy after failure of systemic methotrexate therapy. *Am J Obstet Gynecol.* 2010, 202: e4-e6
6. Zakaria MA, Abdallah ME, Shavell VI, Berman JM, Diamond MP, Knak DC. Conservative management of cervical ectopic pregnancy: utility of uterine artery embolization. *Fertil Steril.* 2011, 95: 872-876
7. Jung SE, Byun JY, Lee JM, Choi BG, Hahn ST. Characteristic MR findings of cervical pregnancy. *J Magn Reson Imaging.* 2001, 13:918-922
8. Ushakov FB, Elchalal U, Aceman PJ, Schenker JG. Cervical pregnancy: Past and future. *Obstet Gynecol Surv.* 1997, 52: 45- 59
9. Ruano R, Reya F, Picone O, et al. Threedimensional ultrasonographic diagnosis of a cervical pregnancy. *Clinics (Sao Paulo).* 2006, 61:355-358
10. Sharma A, Ojha R, Mondal S, Chattopadhyay S, Sengupta P. Niger Med J. Cervical intramural pregnancy: Report of a rare case. *Niger Med J.* 2013 54:271-273.

11. Pantelis A, Daniilidis A, Dinas K. Hippokratia. Conservative treatment of a 7 week cervical ectopic pregnancy after intra-uterine insemination. *Hippokratia*. 2013, 17:95
12. Kirk E, Condous G, Haider Z, Syed A, Ojha K, Bourne T. The conservative management of cervical ectopic pregnancies. *Ultrasound Obstet Gynecol*. 2006, 27: 430- 437
13. Spitzer D, Steiner H, Graf A, Zajc M, Staudach A. Conservative treatment of cervical pregnancy by curettage and local prostaglandin injection. *Hum Reprod*. 1997, 12:860-866
14. Frates MC, Benson CB, Doubilet PM, et al. Cervical ectopic pregnancy: results of conservative treatment. *Radiology*. 1994, 191:773-775
15. Nadisauskiene R, Vaicekavicius E, Taraseviciene V, Simanaviciute D. Conservative treatment of cervical pregnancy with selective unilateral uterine artery embolization. *Medicina (Kaunas)*. 2007, 43:883-886
16. Martinelli P, Maruotti GM, Oppedisano R, et al. Is uterine artery embolization for cervical ectopic pregnancy always safe? *J Minim Invasive Gynecol*. 2007, 14:758-763
17. Trambert JJ, Einstein MH, Banks E, Frost A, Goldberg GL. Uterine artery embolization in the management of vaginal bleeding from cervical pregnancy: a case series. *J Reprod Med*. 2005, 50:844-850